

---

---

**LIPOFILLING  
AND**

**AESTHETIC  
FACIAL**

**PRP  
FOR**

**REJUVENATION**

**UNDERSTANDING AND AUGMENTING  
THE LIPOGRAFT**

---

---

**Joep C.N. Willemsen**



# **Lipofilling and PRP for Aesthetic Facial Rejuvenation**

Understanding and augmenting the lipograft

Joep C.N. Willemsen

---

**Formation and publication of this thesis was possible by generous contribution from Bergman Clinics**



Focus.Aandacht.Resultaat.

**Additional financial and technical support was contributed by:**

University of Groningen (RUG)

Groningen University Institute for Drug Exploration (GUIDE)

Department of Plastic Surgery University Medical Center Groningen (UMCG)



**GILSING WONEN**  
Z E V E N A A R

Willemsen, J.C.N.

Lipofilling and PRP for Aesthetic Facial Rejuvenation: Understanding and augmenting the lipograft

ISBN: 978-94-034-0611-4 (printed version)

ISBN: 978-94-034-0610-7 (electronic version)

Layout: J.C.N. Willemsen and NCP B.V.

Printing: Iskamp printing B.V.

© J.C.N. Willemsen 2018

All rights reserved. No part of this book may be reproduced, stored in a retrieval system, or transmitted in any form or by any means, electronic, mechanical, by photocopying, recording, or otherwise, without the written permission of the author, or, when appropriate, of the publisher of the publication.



rijksuniversiteit  
 groningen

# Lipofilling and PRP for Aesthetic Facial Rejuvenation

Understanding and augmenting the lipograft

## Proefschrift

ter verkrijging van de graad van doctor aan de  
 Rijksuniversiteit Groningen  
 op gezag van de  
 rector magnificus prof. dr. E. Sterken  
 en volgens besluit van het College voor Promoties.

De openbare verdediging zal plaatsvinden op

woensdag 11 april 2018 om 12.45 uur

door

**Joep Carlus Natasja Willemsen**

geboren op 11 oktober 1984  
 te Zevenaar

---

**Promotores**

Prof. dr. B. van der Lei  
Prof. dr. M.C. Harmsen

**Copromotor**

Dr. H.P.J.D. Stevens

**Beoordelingscommissie**

Prof. dr. D. Ulrich  
Prof. dr. R. van der Hulst  
Prof. dr. R.A. Bank

---

---

**Paranimfen**

Drs. E.J.P.M ten Dam

Drs. A.J.H. Engels

---

# TABLE OF CONTENTS

<b>Chapter 1</b> General introduction and outline of this thesis	<b>8</b>
<b>Chapter 2</b> Lipofilling in MACS lifting enhances rejuvenation	<b>20</b>
<b>Chapter 3</b> The effects of platelet rich plasma on recovery time and aesthetic outcome in facial rejuvenation: preliminary retrospective observations	<b>32</b>
<b>Chapter 4</b> The addition of PRP to facial lipofilling: a double-blind placebo-controlled randomized trial	<b>44</b>
<b>Chapter 5</b> The concentration depended effect of Platelet rich plasma on Adipose Stem Cells in vitro	<b>62</b>



<b>Chapter 6</b> The power of fat and its adipose-derived stromal cells: emerging concepts for fibrotic scar treatment	<b>82</b>
<b>Chapter 7</b> General discussion and future perspectives	<b>108</b>
<b>Chapter 8</b> Summary	<b>118</b>
<b>Chapter 9</b> Addendum	<b>124</b>

---

---

# I

## GENERAL INTRODUCTION AND OUTLINE OF THIS THESIS



1. JOEP C.N. WILLEMSSEN

*Introduction*

A general introduction to this thesis and topic of discussion.

*Definition and historical perspectives of lipofilling*

Defining the topic of discussion and some historical notes.

*Factors involved*

Introduction to various succes determining factors within lipofilling. Introduction to regenerative characteristics of the lipograft.

*Aims and outline of this thesis*

Describing the aims and outline of this thesis.

## Aesthetic rejuvenation of the aging face

The natural process of aging results in the gradual impairment in function of individual cells and structural components including bones, muscles, and ligaments<sup>1,3</sup>. While decreased function of vital organs might be not that visible, facial appearance is clearly visible and determines the perception of aging. Since signs of aging are associated with getting older, and being old is associated with many negative feelings in our society, especially among women, many women seek for rejuvenation procedures<sup>4</sup>. Actually, to 'rejuvenate' means 'to make young again'.

Traditionally it was thought that the effects of gravity and loss of skin elasticity due to collagen degradation were the most important factors of aging. For that reason, plastic surgeons devised several surgical methods and procedures to reposition the sagged soft tissue in vertical direction to counteract the effects of gravity, such as e.g. the classical facelift procedure<sup>5</sup>. Due to increased insight into the (facial) aging processes<sup>3,6,7</sup>, however, we have become aware that lifting procedures alone are insufficient to achieve a natural rejuvenation of the aging face in the majority of patients<sup>8,9</sup>. In addition, the loss of volume due to fat atrophy and bone resorption<sup>3,7</sup> has proven to be a major factor in facial aging and, therefore, also has to be addressed to get a natural rejuvenation. Thus, in order to 'truly' rejuvenate the face, one must also restore the volume loss. This should preferably be done with autologous by means of lipofilling: the transfer of autologous harvested fat cells to areas of fat depletion and volume loss.

## Definition and historical perspectives of lipofilling:

Lipofilling is the harvesting of fat by liposuction, which is then injected into the desired region of the body for volume enhancement; this is in fact a fat cell transplantation<sup>10</sup>.

The technique of lipofilling is not new: more than 125 years ago, the 'alleged potential "of living fat cells as filler was already explored"<sup>11</sup>. Since the beginning of 'modern' plastic, reconstructive and aesthetic surgery, the potential use of adipose tissue in lipofilling was examined. Gustav Neuber, just after having completed the construction of the first sterile operating theater in the world in Kiel, Germany (1893), was the first to use fat in correcting a scar after osteomyelitis of the orbital rim. In 1895, Vincenz Czerny used a lipoma for breast reconstruction after mastectomy. Eugene Hollander in the "Handbuch der Kosmetik" showed the first pictures of a lipotransfer for lipoatrophy of the face and a retracted defects of the chest<sup>11</sup>. Results at that time were dismissed as 'moderate' and highly variable in nature. Charles Miller, a controversial doctor from Chicago, published in 1912: "Cosmetic Surgery: The correction of Featural Imperfections", in which he was the first to describe the use of a cannulas to inject living fat cells. In a newspaper interview, the established medical order at that time (1908) ridiculed him and expressed hostilities to his interest in elective surgery and the use of fat. This lead to rejecting his manuscripts for publication and, as a consequence, many years of skepticism, which, in addition, was also due to other doctors being unable to reproduce his results. Only in the second half of the 20th century, lipofilling came back into the spotlights. Yves-Gerard Illouz introduced the regular use of liposuction but also reused the lipoaspirate for lipofilling of the breast<sup>10</sup>. Pierre Fournier propagated harvesting of fat by suction with a sharp syringe<sup>12</sup>. In 2009, they presented their 25 years of experience with lipofilling together at the EMEA in Paris. The technique became even more popular by further pioneering work of Sidney Coleman, Plastic Surgeon, New York, who improved the reproducibility of the lipograft by centrifuging the lipoaspirate prior to injection<sup>13</sup>. Until then, 'decantation' was preferred (separating the water fraction from the lipoaspirate by gravity). The quantity of living fat cells

retrieved by the decantation technique was variable and unpredictable, varying from 20 to 50%<sup>14,15</sup>. Separation by centrifugation, however, improved this quantity up to 85-90%<sup>16-18</sup>. These improvements in the processing of the lipograft significantly improved graft take predictability after lipofilling, and resulted in widespread use of lipofilling for various conditions. Nowadays, lipofilling has become an inevitable tool used in our daily practice of plastic surgery<sup>19</sup>.

#### *More than filling alone: rejuvenation by the ASC?*

During the last two decades, it became apparent that multipotent or precursor cells were present in subcutaneous fat<sup>20</sup>. Harvesting and classifying these cells, however, proved to be a technical challenge. The introduction of liposuction changed this: for the first time, there was access to large volumes of living human fat cells. Zuk et al<sup>21</sup> showed in their study that fat indeed contains precursor cells or adipose derived stem cells (ASC). These findings lead to major advances in stem cell related tissue engineering and regenerative medicine. The ASC almost have the same differentiation as other stem cells<sup>22</sup>, but are actually readily available and easy to separate from fat tissue<sup>23</sup>.

With the introduction of lipofilling also in more superficial areas, it became apparent, as Coleman stated in 2006<sup>24</sup>, that "lipofilling might be more than filling alone" and also had some local rejuvenation effects. In several cases of lipofilling of the face, the overlying skin showed changes: small wrinkles disappeared, pore size decreased, and pigmentation improved. Scars seemed to fade, and felt more similar to normal skin. These first observations lead to several studies that evaluated these rejuvenating properties. In 2007, Rigotti et al.<sup>25</sup> in their study "Clinical treatment of radiotherapy tissue damage by lipoaspirate transplant: a healing process mediated by adipose-derived adult stem cells" introduced a new method in treating irradiated skin: lipofilling was used as a therapy to repair the damaged skin instead of using it for volumetric correction. Rigotti suggested that the positive rejuvenating effects reported in the study might be attributed to ASCs that are abundantly present in the lipograft.

The pioneering work of Rigotti et al resulted in a new form of medicine: regenerative medicine. Confirmation of his results and the first insights into the fundamental backgrounds were presented in the study of Sultan et al,<sup>26</sup> a placebo controlled animal study. Mice underwent radiation: one group received lipofilling of the radiated area; the other group a placebo treatment. Lipofilling significantly improved the negative side effects of the acute radiodermatitis. This observation was further supported by histological findings: there was significant less fibrosis and SMAD3 expression (fibrosis marker) in the areas treated with lipofilling compared to the placebo treated areas. The authors suggest that these effects might be due to the ASC, either by neo angiogenesis or inhibiting the TGF- $\beta$  myofibroblast activity.

The regenerative properties of the lipograft were soon used for other types of skin damage, as, e.g., thermal injuries. Klinger et al.<sup>27</sup> were the first to present a small case series (n=3) that were treated with lipofilling after hemifacial 2nd to 3th degree burns. Klinger concluded that: "lipofilling improves scar quality and suggest a tissue regeneration enhancing process". The group of Sultans et al (as described above) also conducted a placebo controlled mice study that explored the possibility of using lipofilling to minimize scarring after thermal injury<sup>28</sup>. The mice that received lipofilling directly after administering the thermal injury showed increased neo angiogenesis of the area, as measured with a duplex Doppler and as shown by cellular expression of related genes. Similar to the experiments in irradiated mice, a lower amount of fibrosis was observed in the thermal injured areas treated with lipofilling. The authors suggested that the ASC might take over or assist the endothelial progenitor cells, which are

of paramount importance for neo-angiogenesis after thermal injury. It is widely known that with severe thermal injury, the endothelial progenitor cells response from the bone marrow is slow, or even absent<sup>29</sup>. The resulting hypoxia of the injured tissue will result in a high TGF- $\beta$  expression that results in severe scarring and can be counteracted by ADC's or lipofilling. With lipofilling as a potential scar formation reducing therapy in mind, the first clinical trials subsequently appeared. Ribuffo et al.<sup>30</sup>, Balkin et al.<sup>31</sup> and Zellner et al.<sup>32</sup> reported significant scar reduction and modulation of existing scar tissue in a controlled clinical setting.

Rigotti was also able to prove his concept in a small clinical histology study: lipofilling of normal aged skin increased the elastin content in the dermis<sup>33</sup>. Although the study lacked a control group, many authors conclude that this observation explains the rejuvenating effect seen in aesthetic facial lipofilling. Unfortunately, the study of Rigotti et al. did not show histological findings of significance underlining the observed clinical rejuvenating effect.

Besides scar reduction therapies, several studies explored the pain reducing effect of lipofilling around peripheral neuropathy<sup>34</sup>, as well as wound closure of diabetic ulcers<sup>35, 36</sup>, all reporting a significant variation in effects from hardly none to superior results.

In recent years, the focus of research shifted more and more from the entire lipograft to the specific ASC's. New methods of isolating and cultivating ASC from the lipograft initiated the start of new stem cell therapies and ASC, SVF (Stromal vascular fraction) boosted lipofilling, all demonstrating promising results<sup>37-39</sup>. These new forms of stem cell associated therapies fall outside the scope of this thesis, and were not further included or studied.

## Optimizing results: factors involved in lipograft survival

Ever since the introduction of lipofilling, a lot of controversy exists about the 'survival' of transplanted fat. It is known that new vascular ingrowth starts from day 7 after transplantation<sup>40</sup> and that fat necrosis peaks at day 30<sup>40</sup>. Already two months after lipofilling, biopsies obtained from the grafted fat in several animal studies showed a well vascularized sample of tissue with living functional cells<sup>40, 41</sup>. Graft retention available from clinical studies is reported to be between 55% and 82% in the breast<sup>42-44</sup>, and 32%-70%<sup>45, 46</sup> in the midface. However, it has to be noted that the number of high level evidence studies is limited (n=32) and that only 8 studies are available thus far that have used 3D imaging techniques to determine volume retention. Focusing on lipofilling of the midface, the study of Swanson was the first to explore the survival of fat grafts in the face by analyzing the lipograft volume by means of multiple MRI scans<sup>46</sup>. Although limited by the small number of patients, this study clearly demonstrated a stable lipograft volume after 6 months, with a similar density on the MRI as 'normal' fat tissue. The authors also noted that there was no significant difference in graft volume between 1 and 6 months after lipofilling, suggesting adequate vascularization and survival of the remaining cells in the lipograft. More recently, the study of Meier et al found similar results, but reported a lower percentage of graft take<sup>45</sup>.

Even though lipofilling has been performed for decades, no consensus exists about the best fat-grafting technique<sup>47</sup>. Location of donor sites, use of local anesthetics, harvesting methods, processing techniques, and injection techniques all continue to be points of discussion<sup>40, 47-50</sup>. The recent evidence based-review of Sinno et al. discusses the variation in fat grafting and their level of evidence<sup>51</sup>. The authors drew the following conclusions: (a) liposuction location (e.g. donor location as abdomen, thigh) has no influence on fat graft survival; (b) the use of

a liposuction pump results in similar graft viability as compared to liposuction by syringe aspiration; (c) washing of fat is not superior to other processing methods when looking at viability; (d) lipofilling should take place as soon as possible after liposuction; (e) the use of low-shear devices with a large diameter for injection improves the graft take compared to small diameter cannulas. The level of evidence of all these aforementioned conclusions is, however, low, also regarding the enormous variation in clinical practice, which goes on in a frequency much faster than the underlying scientific evidence. Furthermore, recent theories focus more on the crucial role of adipose-derived stromal/stem cells (ASC) <sup>52-54</sup> and/or growth factors such as vascular endothelial growth factor (VEGF) <sup>55-57</sup> in fat graft survival rather than adipocyte viability, adding another variable with lots of uncertainties.

#### *The role of the ASC in graft survival.*

ASC play a key role in the lipofilling attributed regenerative effects and their number in a lipograft seems to correlate with graft survival. Early studies from Gentile et al. in the breast suggested improvement of graft take when the ratio of ASC was increased in lipograft<sup>58</sup>. Peltoniemi et al, however, found no beneficial clinical effect of increased number of ADC's<sup>59</sup>. More recently, the study of Kolle et al clearly demonstrated a significantly better graft take of ASC enriched lipograft over normal lipografts<sup>54</sup>. From a fundamental point of view, the ASC could attribute to graft retention by several mechanisms: by (1) direct support of adipocytes during the first days after transplantation, by (2) inhibition of apoptosis pathways of adipocytes, by (3) supporting vascular ingrowth by direct or indirect effects on endothelial cells and last but not least by (4) differentiation into adipocytes.

#### *Platelet Rich Plasma (PRP)*

Platelet-rich plasma (PRP) is defined as the portion of the plasma fraction of autologous blood having a platelet concentration above baseline<sup>60</sup>. PRP also has been named platelet-enriched plasma, platelet-rich concentrate, autologous platelet gel. Platelet Rich Plasma (PRP) was already used in orthopedic medicine for decades<sup>61</sup>, but made its introduction into plastic surgery only very recently. Adding a high concentration of platelets directly to the lipograft or injecting it in the acceptor area will release an additional tremendous amount of growth factors. These growth factors are associated with wound healing and some of them such as the Vascular Endothelial Growth Factor (VEGF) and Platelet Derived Growth Factor (PDGF) <sup>62</sup> are pro-angiogenic<sup>63-65</sup>. Nowadays there are many indications for the use of PRP, ranging from wound treatment to per-operative application in orthopedics and surgery, and facial skin rejuvenation procedures such as micro-needling<sup>61, 62, 66</sup>. Literature has clearly demonstrated that PRP results in faster wound closure of chronic ulcers<sup>67, 68</sup>, speeds up recovery time after facial aesthetic laser treatments<sup>69, 70</sup> and increases the healing rate and tensile strength after tenorrhaphy<sup>71-74</sup>.

## **PRP added to the lipograft**

Although prospective human studies are limited in number and show contradictory results to this date, there are many promising placebo controlled animal studies that did show impressive effects when adding PRP to the lipograft. Oh et al.<sup>75</sup> and Nakamura et al.<sup>76</sup> demonstrated that adding PRP to the lipograft resulted in a significant higher fat retention with increased vessel formation. The right concentration (4-5x times above baseline) of the PRP seems to be of paramount importance in achieving these effects<sup>77</sup>. High concentration PRP can even be detrimental, as supported by studies on other cell lines like fibroblasts and osteoblasts<sup>64, 78-80</sup>. Several fundamental studies presented findings that could explain the positive effect of PRP

on the lipograft: Graft take might be improved by PRP because it stimulates ASC proliferation<sup>51</sup>, blocks the pathways of apoptosis<sup>52</sup> and helps differentiation to adipocytes<sup>53</sup>. Moreover, PRP lysate stimulates proliferation, migration and tube formation of human umbilical vein endothelial cells both in vitro as well as in a nude mouse model<sup>54</sup>. Furthermore, PRP induces changes on endothelial cells that can contribute to (neo)angiogenesis of the fat graft, thereby enhancing fat graft survival<sup>55</sup>.

The use of PRP as an additive to lipofilling is fiercely debated in literature. Thus far, clinical evidence is limited and studies evaluating the effect of PRP vary significantly in methodology<sup>81</sup>. How PRP exactly improves graft take remains unclear: the growth factors may influence the ASC in the lipograft, the adipocyte, the donor area, or a combination of all these factors.

There is currently also limited evidence that direct subcutaneous injection of PRP may improve the quality of the dermal layer<sup>82-84</sup>. A limited number of studies reported an increase of skin homogeneity, texture and elasticity after PRP injection<sup>85-87</sup>. These observations have stimulated us to additional addition of PRP to the lipograft to enhance the rejuvenation effect when using it in combination with facial lipofilling.

## **Aims and outline of this thesis**

The main objective of this thesis is to further analyze the (clinical) effect of lipofilling on facial rejuvenation and to investigate the specific role of PRP when adding it to the lipograft. In order to get a clear view on these aforementioned aspects, six separate study objectives were identified and performed:

- (1) determining the possible improvement in aesthetic outcome when lipofilling is combined to face-lifting procedures,*
- (2) investigating the potential beneficiary effect of PRP when adding it to the lipograft in facial lipofilling, both on overall aesthetic outcome as recovery time after surgery retrospectively,*
- (3) investigating the potential beneficiary effect of adding PRP to the lipograft in facial lipofilling on skin elasticity, volume retention and recovery time (double blinded randomized controlled trial)*
- (4) exploring the rejuvenating effect of lipofilling on overlying skin as defined by skin elasticity,*
- (5) investigating the concentration depended effect of PRP on ASC, and last but not least*
- (6) investigating the role of the ASC in the lipograft and rejuvenation.*

The possible improvement in aesthetic outcome when lipofilling is combined with face-lifting procedures is presented in Chapter II, in which we compare facial improvement after either face lifting without or with lipofilling. In Chapter III, we retrospectively analyze whether PRP has a beneficiary effect on the overall aesthetic outcome and recovery time when used in combination with lipofilling, or in combination with face lifting and lipofilling. In Chapter IV we analyze in a double blinded randomized trial the beneficiary effect of PRP to facial lipofilling with regard to skin elasticity, volume retention and recovery time. The in vitro concentration dependent effect of PRP on ASC proliferation and function is presented in Chapter V, and the role of the ASC in rejuvenation, as is known from literature up till date, is reviewed in Chapter VI. Finally, Chapter VII summarizes and discusses all results of this thesis, along with the personal future vision on the subject studied by the candidate.



## References

1. Cotofana S, Fratila AA, Schenck TL, Redka-Swoboda W, Zilinsky I, Pavicic T. The anatomy of the aging face: A review. *Facial Plast Surg.* 2016;32:253-260.
2. Ezure T, Amano S. Influence of subcutaneous adipose tissue mass on dermal elasticity and sagging severity in lower cheek. *Skin Res Technol.* 2010;16:332-338.
3. Fitzgerald R, Graivier MH, Kane M et al. Update on facial aging. *Aesthetic surgery journal / the American Society for Aesthetic Plastic surgery.* 2010;30 Suppl:11S-24S.
4. Klassen AF, Cano SJ, Alderman A et al. Self-report scales to measure expectations and appearance-related psychosocial distress in patients seeking cosmetic treatments. *Aesthet Surg J.* 2016;36:1068-1078.
5. Tonnard P, Verpaele A, Monstrey S et al. Minimal access cranial suspension lift: A modified S-lift. *Plastic and reconstructive surgery.* 2002;109:2074-86.
6. Lam SM. A new paradigm for the aging face. *Facial plastic surgery clinics of North America.* 2010;18:1-6.
7. Richard MJ, Morris C, Deen BF, Gray L, Woodward JA. Analysis of the anatomic changes of the aging facial skeleton using computer-assisted tomography. 2009;25:382-386.
8. Pontius AT, Williams EF,3rd. The evolution of midface rejuvenation: Combining the midface-lift and fat transfer. 2006;8:300-305.
9. Ramirez OM. Full face rejuvenation in three dimensions: A "face-lifting" for the new millennium. *Aesthetic Plast Surg.* 2001;25:152-164.
10. Illouz YG. Body contouring by lipolysis: A 5-year experience with over 3000 cases. *Plast Reconstr Surg.* 1983;72:591-597.
11. Holländer E. *Handbuch der kosmetik.* Leipzig: Veit & Comp.; 1912.
12. Fournier PF, Otteni FM. Lipodissection in body sculpturing: The dry procedure. *Plast Reconstr Surg.* 1983;72:598-609.
13. Coleman SR. Facial recontouring with lipostructure. 1997;24:347-367.
14. Zhu M, Cohen SR, Hicok KC et al. Comparison of three different fat graft preparation methods: Gravity separation, centrifugation, and simultaneous washing with filtration in a closed system. *Plast Reconstr Surg.* 2013;131:873-880.
15. Hoareau L, Bencharif K, Girard AC et al. Effect of centrifugation and washing on adipose graft viability: A new method to improve graft efficiency. *J Plast Reconstr Aesthet Surg.* 2013.
16. Rohrich RJ, Sorokin ES, Brown SA. In search of improved fat transfer viability: A quantitative analysis of the role of centrifugation and harvest site. *Plastic and reconstructive surgery.* 2004;113:391-5; discussion 396-7.
17. Conde-Green A, de Amorim NF, Pitanguy I. Influence of decantation, washing and centrifugation on adipocyte and mesenchymal stem cell content of aspirated adipose tissue: A comparative study. *J Plast Reconstr Aesthet Surg.* 2010;63:1375-1381.
18. Pu LL, Coleman SR, Cui X, Ferguson RE,Jr., Vasconez HC. Autologous fat grafts harvested and refined by the coleman technique: A comparative study. 2008;122:932-937.
19. Hsu VM, Stransky CA, Bucky LP, Percec I. Fat grafting's past, present, and future: Why adipose tissue is emerging as a critical link to the advancement of regenerative medicine. *Aesthet Surg J.* 2012;32:892-899.
20. ROdBELL M. Localization of lipoprotein lipase in fat cells of rat adipose tissue. *J Biol Chem.* 1964;239:753-755.
21. Zuk PA, Zhu M, Ashjian P et al. Human adipose tissue is a source of multipotent stem cells. *Molecular biology of the cell.* 2002;13:4279-95.
22. Sterodimas A, de Faria J, Nicaretta B, Pitanguy I. Tissue engineering with adipose-derived stem cells (ADSCs): Current and future applications. *J Plast Reconstr Aesthet Surg.* 2010;63:1886-1892.
23. Ogawa R. The importance of adipose-derived stem cells and vascularized tissue regeneration in the field of tissue transplantation. *Curr Stem Cell Res Ther.* 2006;1:13-20.
24. Coleman SR. Structural fat grafting: More than a permanent filler. *Plastic and reconstructive surgery.* 2006;118:108S-120S.
25. Rigotti G, Marchi A, Galie M et al. Clinical treatment of radiotherapy tissue damage by lipoaspirate transplant: A healing process mediated by adipose-derived adult stem cells. *Plastic and reconstructive*

surgery. 2007;119:1409-22; discussion 1423-4.

26. Sultan SM, Stern CS, Allen RJ, Jr et al. Human fat grafting alleviates radiation skin damage in a murine model. *Plast Reconstr Surg*. 2011;128:363-372.

27. Klinger M, Marazzi M, Vigo D, Torre M. Fat injection for cases of severe burn outcomes: A new perspective of scar remodeling and reduction. *Aesthetic plastic surgery*. 2008;32:465-9.

28. Sultan SM, Barr JS, Butala P et al. Fat grafting accelerates revascularisation and decreases fibrosis following thermal injury. *Journal of plastic, reconstructive & aesthetic surgery : JPRAS*. 2012;65:219-27.

29. Rignault-Clerc S, Biemann C, Delodder F et al. Functional late outgrowth endothelial progenitors isolated from peripheral blood of burned patients. *Burns*. 2012.

30. Ribuffo D, Atzeni M. Outcome of different timings of radiotherapy in implant-based breast reconstruction: Clinical evidence of benefit using adipose-derived stem cells. *Plast Reconstr Surg*. 2012;130:498e-9e.

31. Balkin DM, Samra S, Steinbacher DM. Immediate fat grafting in primary cleft lip repair. *J Plast Reconstr Aesthet Surg*. 2014;67:1644-1650.

32. Zellner EG, Pfaff MJ, Steinbacher DM. Fat grafting in primary cleft lip repair. *Plast Reconstr Surg*. 2015;135:1449-1453.

33. Charles-de-Sa L, Gontijo-de-Amorim NF, Maeda Takiya C et al. Antiaging treatment of the facial skin by fat graft and adipose-derived stem cells. *Plast Reconstr Surg*. 2015;135:999-1009.

34. Ulrich D, Ulrich F, van Doorn L, Hovius S. Lipofilling of perineal and vaginal scars: A new method for improvement of pain after episiotomy and perineal laceration. *Plast Reconstr Surg*. 2012;129:593e-594e.

35. Conde-Green A, Marano AA, Lee ES et al. Fat grafting and adipose-derived regenerative cells in burn wound healing and scarring: A systematic review of the literature. *Plast Reconstr Surg*. 2016;137:302-312.

36. Simonacci F, Bertozzi N, Grieco MP, Grignaffini E, Raposio E. Procedure, applications, and outcomes of autologous fat grafting. *Ann Med Surg (Lond)*. 2017;20:49-60.

37. Li J, Gao J, Cha P et al. Supplementing fat grafts with adipose stromal cells for cosmetic facial contouring. *Dermatol Surg*. 2013;39:449-456.

38. Nguyen A, Guo J, Banyard DA et al. Stromal vascular fraction: A regenerative reality? part 1: Current concepts and review of the literature. *J Plast Reconstr Aesthet Surg*. 2016;69:170-179.

39. Gir P, Oni G, Brown SA, Mojallal A, Rohrich RJ. Human adipose stem cells: Current clinical applications. *Plast Reconstr Surg*. 2012;129:1277-1290.

40. Pu LL. Towards more rationalized approach to autologous fat grafting. *Journal of plastic, reconstructive & aesthetic surgery : JPRAS*. 2012;65:413-9.

41. Brucker M, Sati S, Spangenberg A, Weinzeig J. Long-term fate of transplanted autologous fat in a novel rabbit facial model. *Plastic and reconstructive surgery*. 2008;122:749-54.

42. Choi M, Small K, Levovitz C, Lee C, Fadl A, Karp N. The volumetric analysis of fat graft survival in breast reconstruction. *Plast Reconstr Surg*. 2012.

43. Khouri RK, Eisenmann-Klein M, Cardoso E et al. Brava(R) and autologous fat transfer is a safe and effective breast augmentation alternative: Results of a six-year, eighty-one patients prospective multicenter study. *Plastic and reconstructive surgery*. 2012.

44. Largo RD, Tchang LA, Mele V et al. Efficacy, safety and complications of autologous fat grafting to healthy breast tissue: A systematic review. *J Plast Reconstr Aesthet Surg*. 2014;67:437-448.

45. Meier JD, Glasgold RA, Glasgold MJ. Autologous fat grafting: Long-term evidence of its efficacy in midfacial rejuvenation. *Arch Facial Plast Surg*. 2009;11:24-8.

46. Swanson E. Malar augmentation assessed by magnetic resonance imaging in patients after face lift and fat injection. *Plastic and reconstructive surgery*. 2011;127:2057-65.

47. Gir P, Brown SA, Oni G, Kashefi N, Mojallal A, Rohrich RJ. Fat grafting: Evidence-based review on autologous fat harvesting, processing, reinjection, and storage. *Plast Reconstr Surg*. 2012;130:249-258.

48. Kaufman MR, Miller TA, Huang C et al. Autologous fat transfer for facial recontouring: Is there science behind the art?. 2007;119:2287-2296.

49. Strong AL, Cederna PS, Rubin JP, Coleman SR, Levi B. The current state of fat grafting: A review of harvesting, processing, and injection techniques. *Plast Reconstr Surg*. 2015;136:897-912.

50. Tuin AJ, Domerchie PN, Schepers RH et al. What is the current optimal fat grafting processing technique? A systematic review. *J Craniomaxillofac Surg*. 2016;44:45-55.

51. Sinno S, Wilson S, Brownstone N, Levine SM. Current thoughts on fat grafting: Using the evidence to determine fact or fiction. *Plast Reconstr Surg*. 2016;137:818-824.
52. Matsumoto D, Sato K, Gonda K et al. Cell-assisted lipotransfer: Supportive use of human adipose-derived cells for soft tissue augmentation with lipoinjection. *Tissue Eng*. 2006;12:3375-3382.
53. Rigotti G, Charles-de-Sa L, Gontijo-de-Amorim NF et al. Expanded stem cells, stromal-vascular fraction, and platelet-rich plasma enriched fat: Comparing results of different facial rejuvenation approaches in a clinical trial. *Aesthet Surg J*. 2016;36:261-270.
54. Kolle SF, Fischer-Nielsen A, Mathiasen AB et al. Enrichment of autologous fat grafts with ex-vivo expanded adipose tissue-derived stem cells for graft survival: A randomised placebo-controlled trial. *Lancet*. 2013;382:1113-1120.
55. Nishimura T, Hashimoto H, Nakanishi I, Furukawa M. Microvascular angiogenesis and apoptosis in the survival of free fat grafts. 2000;110:1333-1338.
56. Garza RM, Paik KJ, Chung MT et al. Studies in fat grafting: Part III. fat grafting irradiated tissue--improved skin quality and decreased fat graft retention. *Plast Reconstr Surg*. 2014;134:249-257.
57. Liao HT, Marra KG, Rubin JP. Application of platelet-rich plasma and platelet-rich fibrin in fat grafting: Basic science and literature review. *Tissue Eng Part B Rev*. 2014;20:267-276.
58. Gentile P, Orlandi A, Scioli MG et al. A comparative translational study: The combined use of enhanced stromal vascular fraction and platelet-rich plasma improves fat grafting maintenance in breast reconstruction. *Stem Cells Transl Med*. 2012;1:341-351.
59. Peltoniemi HH, Salmi A, Miettinen S et al. Stem cell enrichment does not warrant a higher graft survival in lipofilling of the breast: A prospective comparative study. *J Plast Reconstr Aesthet Surg*. 2013;66:1494-1503.
60. Eppley BL, Pietrzak WS, Blanton M. Platelet-rich plasma: A review of biology and applications in plastic surgery. *Plastic and reconstructive surgery*. 2006;118:147e-159e.
61. Alsousou J, Thompson M, Hulley P, Noble A, Willett K. The biology of platelet-rich plasma and its application in trauma and orthopaedic surgery: A review of the literature. *J Bone Joint Surg Br*. 2009;91:987-996.
62. Lacci KM, Dardik A. Platelet-rich plasma: Support for its use in wound healing. *The Yale journal of biology and medicine*. 2010;83:1-9.
63. Mammoto T, Jiang A, Jiang E, Mammoto A. Platelet rich plasma extract promotes angiogenesis through the angiopoietin1-Tie2 pathway. *Microvasc Res*. 2013;89:15-24.
64. Man Y, Wang P, Guo Y et al. Angiogenic and osteogenic potential of platelet-rich plasma and adipose-derived stem cell laden alginate microspheres. *Biomaterials*. 2012;33:8802-8811.
65. Sommeling CE, Heyneman A, Hoeksema H, Verbelen J, Stillaert FB, Monstrey S. The use of platelet-rich plasma in plastic surgery: A systematic review. *J Plast Reconstr Aesthet Surg*. 2013;66:301-311.
66. Martinez-Zapata MJ, Marti-Carvajal A, Sola I et al. Efficacy and safety of the use of autologous plasma rich in platelets for tissue regeneration: A systematic review. *Transfusion*. 2009;49:44-56.
67. Cervelli V, Gentile P, Grimaldi M. Regenerative surgery: Use of fat grafting combined with platelet-rich plasma for chronic lower-extremity ulcers. *Aesthetic Plast Surg*. 2009;33:340-345.
68. Kim SA, Ryu HW, Lee KS, Cho JW. Application of platelet-rich plasma accelerates the wound healing process in acute and chronic ulcers through rapid migration and upregulation of cyclin A and CDK4 in HaCaT cells. *Mol Med Rep*. 2013;7:476-480.
69. Lee JW, Kim BJ, Kim MN, Mun SK. The efficacy of autologous platelet rich plasma combined with ablative carbon dioxide fractional resurfacing for acne scars: A simultaneous split-face trial. *Dermatologic surgery* : official publication for American Society for Dermatologic Surgery [et al ]. 2011;37:931-8.
70. Na JI, Choi JW, Choi HR et al. Rapid healing and reduced erythema after ablative fractional carbon dioxide laser resurfacing combined with the application of autologous platelet-rich plasma. *Dermatologic surgery* : official publication for American Society for Dermatologic Surgery [et al ]. 2011;37:463-8.
71. de Almeida AM, Demange MK, Sobrado MF, Rodrigues MB, Pedrinelli A, Hernandez AJ. Patellar tendon healing with platelet-rich plasma: A prospective randomized controlled trial. *Am J Sports Med*. 2012;40:1282-1288.
72. Cervellini M, de Girolamo L, Bait C, Denti M, Volpi P. Autologous platelet-rich plasma gel to reduce donor-site morbidity after patellar tendon graft harvesting for anterior cruciate ligament reconstruction:

- A randomized, controlled clinical study. *Knee Surg Sports Traumatol Arthrosc.* 2012;20:114-120.
73. Jo CH, Kim JE, Yoon KS et al. Does platelet-rich plasma accelerate recovery after rotator cuff repair? A prospective cohort study. *The American journal of sports medicine.* 2011;39:2082-90.
74. Dragoo JL, Braun HJ, Durham JL et al. Comparison of the acute inflammatory response of two commercial platelet-rich plasma systems in healthy rabbit tendons. *The American journal of sports medicine.* 2012.
75. Oh DS, Cheon YW, Jeon YR, Lew DH. Activated platelet-rich plasma improves fat graft survival in nude mice: A pilot study. *Dermatologic surgery : official publication for American Society for Dermatologic Surgery [et al].* 2011;37:619-25.
76. Nakamura S, Ishihara M, Takikawa M et al. Platelet-rich plasma (PRP) promotes survival of fat-grafts in rats. *Annals of plastic surgery.* 2010;65:101-6.
77. Mazzocca AD, McCarthy MB, Chowanec DM et al. Platelet-rich plasma differs according to preparation method and human variability. *The Journal of bone and joint surgery American volume.* 2012;94:308-16.
78. Creeper F, Lichanska AM, Marshall RI, Seymour GJ, Ivanovski S. The effect of platelet-rich plasma on osteoblast and periodontal ligament cell migration, proliferation and differentiation. *Journal of periodontal research.* 2009;44:258-65.
79. van den Dolder J, Mooren R, Vloon AP, Stoelinga PJ, Jansen JA. Platelet-rich plasma: Quantification of growth factor levels and the effect on growth and differentiation of rat bone marrow cells. *Tissue engineering.* 2006;12:3067-73.
80. Graziani F, Ivanovski S, Cei S, Ducci F, Tonetti M, Gabriele M. The in vitro effect of different PRP concentrations on osteoblasts and fibroblasts. *Clinical oral implants research.* 2006;17:212-9.
81. Frautschi RS, Hashem AM, Halasa B, Cakmakoglu C, Zins JE. Current evidence for clinical efficacy of platelet rich plasma in aesthetic surgery: A systematic review. *Aesthet Surg J.* 2017;37:353-362.
82. Cho JM, Lee YH, Baek RM, Lee SW. Effect of platelet-rich plasma on ultraviolet b-induced skin wrinkles in nude mice. *J Plast Reconstr Aesthet Surg.* 2010.
83. Kakudo N, Kushida S, Minakata T, Suzuki K, Kusumoto K. Platelet-rich plasma promotes epithelialization and angiogenesis in a splitthickness skin graft donor site. *Med Mol Morphol.* 2011;44:233-236.
84. Cho JW, Kim SA, Lee KS. Platelet-rich plasma induces increased expression of G1 cell cycle regulators, type I collagen, and matrix metalloproteinase-1 in human skin fibroblasts. *Int J Mol Med.* 2012;29:32-36.
85. Redaelli A, Romano D, Marciano A. Face and neck revitalization with platelet-rich plasma (PRP): Clinical outcome in a series of 23 consecutively treated patients. *J Drugs Dermatol.* 2010;9:466-72.
86. Cameli N, Mariano M, Cordone I, Abril E, Masi S, Foddai ML. Autologous pure platelet-rich plasma dermal injections for facial skin rejuvenation: Clinical, instrumental, and flow cytometry assessment. *Dermatol Surg.* 2017;43:826-835.
87. Gawdat HI, Tawdy AM, Hegazy RA, Zakaria MM, Allam RS. Autologous platelet-rich plasma versus readymade growth factors in skin rejuvenation: A split face study. *J Cosmet Dermatol.* 2017.



---

---

# II

## LIPOFILLING IN MACS LIFTING ENHANCES REJUVENATION

- 
1. JOEP C.N. WILLEMSSEN
  2. KARLIJN M. MULDER
  3. HIERONYMUS P.J.D. STEVENS

### *Introduction*

Loss of volume seems an important aspect in facial aging, at the same time its relevance is frequently neglected. In this study, we investigated the relevance of lipofilling as an ancillary procedure to improve the impact of a facelifting procedure.

### *Results*

MACS-lifting combined with lipofilling yielded overall cosmetic results that were significantly better than results obtained by MACS-lifting alone. The photographic evaluations showed that improvements were more pronounced in the tear trough ( $p < 0.05$ ) and malar eminence ( $p < 0.01$ ) than in the nasolabial groove ( $p > 0.05$ ).

### *Material and Methods*

A retrospective analysis of a cohort of 50 cases of MACS lifting (Minimal Access Cranial Suspension) versus 42 cases of MACS lifting with adjuvant lipofilling was performed. Results were evaluated using a photographic ranking system by two different panels (five plastic surgeons and five medical students).

### *Conclusion*

Volume restoration with lipofilling, following MACS-lifting, produces significantly better postoperative results than MACS-lifting alone. The most pronounced improvements are seen in the region of the tear trough and malar eminence.

## Introduction

To obtain the most natural appearing rejuvenation of the ageing face, it is becoming increasingly accepted that lifting alone is not sufficient in the majority of cases<sup>1-6</sup>. Important factors resulting in ageing of the face are: the effect of gravity, the loss of skin elasticity (due to collagen degradation) and the loss of volume (due to fat atrophy<sup>7-9</sup> and bone resorption<sup>10,11</sup>). Especially the loss of volume is nowadays seen as a major factor in aging of the face<sup>12</sup>. Repositioning the soft tissue along a vertical vector has been demonstrated to rejuvenate the face in an aesthetically pleasing manner<sup>5,7,13,14</sup>. Our aim was to investigate the relevance of lipofilling, also commonly referred to as autologous microfat grafting, as an ancillary procedure to augment the results in short scar vertical vector face lifting. All patients included in this study received vertical repositioning by a Minimal Access Cranial Suspension (MACS) lift<sup>15,16</sup>.

## Patients and Methods

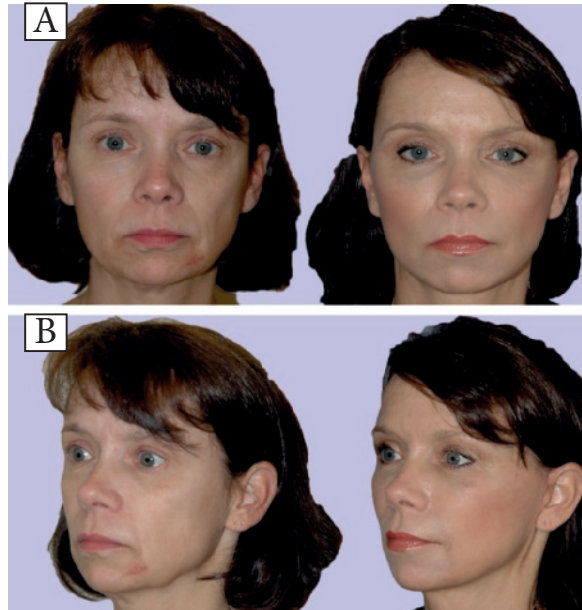### *Surgical technique*

MACS lifting was undertaken as described by Tonnard and Verpaele<sup>15,16</sup>, with minor modifications only. A curved pre-trageal incision was used, running vertically upward into the sideburn. Subcutaneous dissection was extended to the anterior border of the parotid gland, extended 4 cm under the angle of the mandible, revealing the Platysma muscle clearly. One cm cranial to the helical root, a pretragal purse-string suture was anchored to the deep temporalis fascia. Incorporating the SMAS overlying the parotid gland the first purse-string suture runs inferiorly in a narrow U-shape well beyond the angle of the mandible including the Platysma muscle firmly, before returning to the starting point 1 cm anterior to the first leg of the suture. This most caudal point of the suture loop was placed lower than initially described to enable a more pronounced effect in flattening the floor of the mouth by a pulley-effect over the mandible when lifting the Platysma muscle vertically. The second purse-string suture was more O-shaped. It was placed from the same starting point but directed to the extent of the subcutaneous dissection. The entire procedure is also clarified in video on [www.surgytec.com](http://www.surgytec.com) (<http://www.surgytec.com/video/xmacs-lifting-7-tips-to-reduce-operating-time-and-improve-results>).

In cases where loss of volume was a clear part of the ageing process, lipofilling was performed, either during the MACS-lift or within 1 year after initial surgery. The Coleman technique<sup>9,17</sup> for fat harvesting and injection was used but refined by using a smaller custom made canula for harvesting (inner diameter 1.3 mm). Donor sites were the abdomen and the upper legs in all patients. The upper legs were the preferred donor site for harvesting for practical reasons. In female clients the upper legs proved to yield consistent quantities of high quality fat, that could be removed with minimal trauma to the graft and minimal discomfort to the patient. The abdomen yielded less consistent quantities of usable fat compared to the upper legs, particularly in thinner patients. In those cases the percentage of disrupted fat cells leaving a larger oily fraction after centrifugation was higher. Approximately 2-3 times more fat was harvested than the estimated amount required for the procedure. Fat was centrifuged for 3 minutes at the maximum speed of 3000RPM (IEC MediSpin Centrifuge), after which the oil (top layer) and serum/infiltrate layers (bottom layer) were drained away, preserving the pre-adipocyte-rich pellet<sup>18</sup>. Fat injection was performed using a short curved Coleman canula in 1mm aliquots. Between 13 to 23 cc of fat was injected in the deep subcutaneous plane in each side of the face, except for the lower lid/tear trough region, where the injection was performed in the supraperiosteal/submuscular plane and the temporal area were the level of injection



was above the superficial fascia of the Temporal muscle. Lipofilling could be performed in conjunction with a MACS lift without difficulties as the target zones for injection were outside of the MACS-lift dissection area.



**Figure I.** Examples of photographs presented to panel members for photo ranking analysis. A: anterior-posterior view, B: three-quarter view.

#### *Patient groups & evaluation of results*

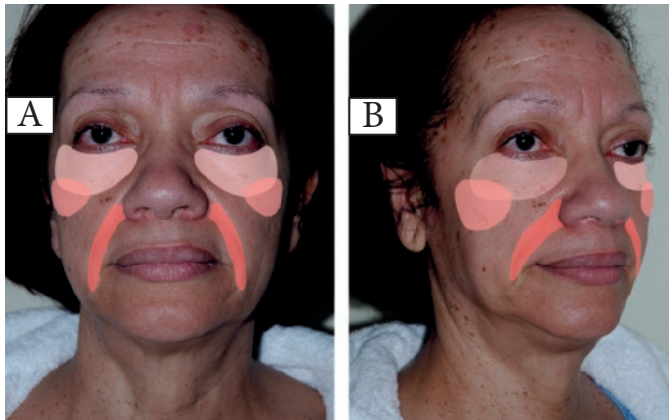
After initial experience with 200 MACS liftings between 2000 and 2006, a study evaluating the effect of adding lipofilling to the MACS lift was started from 2006 onwards. Subsequently, two groups were defined; group A (n=50): patients with MACS lifting only; group B (n=42): patients treated with MACS-lifting with adjuvant lipofilling, performed simultaneously or within one year after MACS-lifting. A minimal follow-up period of 6 months, without any other facial surgical procedure during that time, was required for inclusion. Groups did not differ significantly in age, smoking behavior or body mass index. The senior author, with extensive experience in facial cosmetic surgery and lipofilling prior to the trial, performed surgery in both groups. All patients receiving a MACS lifting were treated using exactly the same technique as described above.

From each of the two groups (50 cases in Group A and 42 in Group B), pre- and postoperative photographs were obtained from 16 patients, randomly selected by an independent statistician, making two times two sets of 8 photos to be analyzed. Each set of 8 photos was holding 4 cases from group A and 4 cases from group B. Two panels were asked in a single-blinded fashion, to evaluate frontal and three-quarter view of pre- and postoperative photographs for every patient (see Figure I). No patient information was provided. One panel consisted of five plastic surgeons, the other of five medical students. Individual panel member were asked to assess

improvement of the pre- versus postoperative photo per case presented and rank the results by placing the photos in a row on a table from best to least improvement. Each ranked photo received a score ranging from 8 (for the best improvement) to 1 ( for the least improvement). Three different aesthetic zones in the face were evaluated - Zone 1 represented the tear trough / nasojugal groove; Zone 2 the nasolabial crease and Zone 3 the malar eminence (Figure II).

### *Statistical analyses*

Scores derived from ranking the photographs were summed and grouped according to the view and aesthetic zone (see Table I). Statistical comparisons were performed using a student-t test. All data analysis was performed with the SPSS statistical package (version 16.02 for Windows, SPSS Inc, Chicago, IL).



**Figure II.** Shaded areas represent the different zones that were targeted for evaluation in our study. Zone 1(lightest color) represents the tear trough/nasojugal groove, zone 2 (darkest color) represents the nasolabial crease, zone 3 represents the malar eminence (intermediate color).

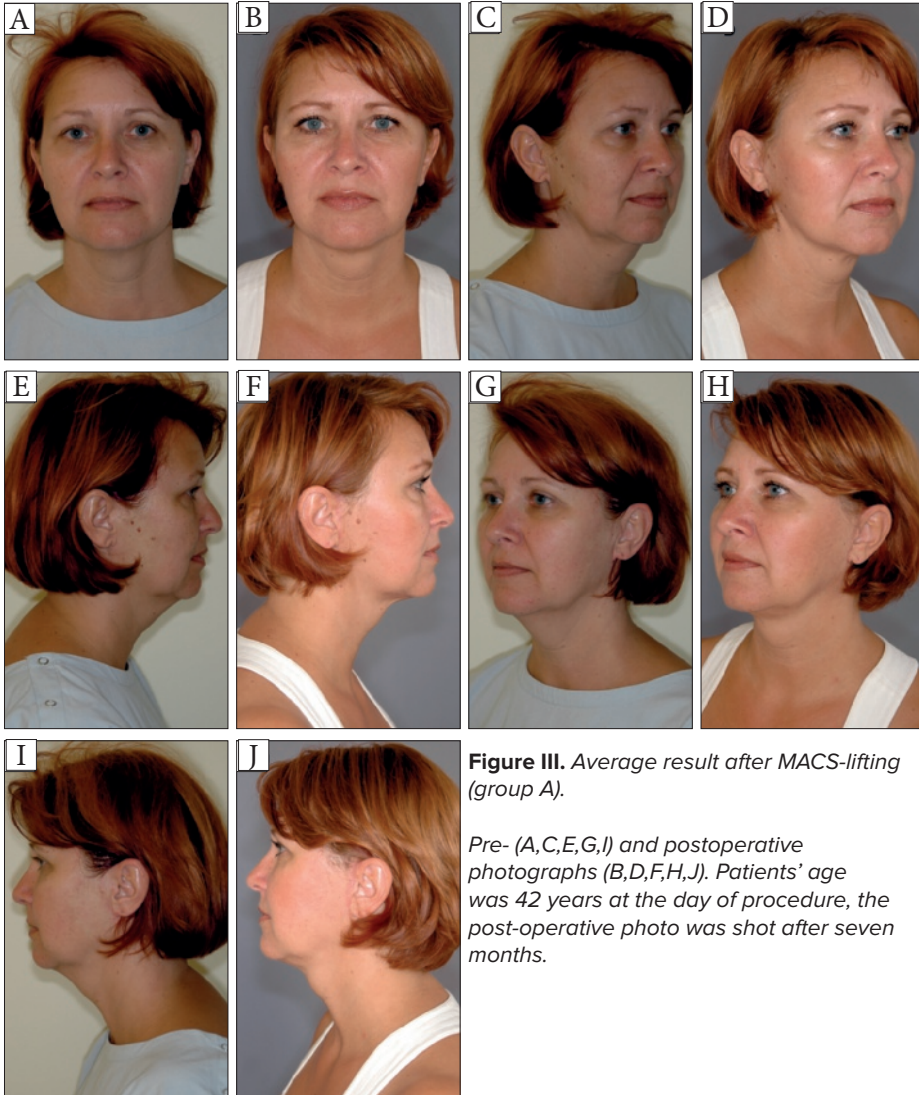A: anterior-posterior view, B: three-quarter view.

All patients in Group B received lipofilling in these areas.

## **Results**

### *Results from the photographic comparisons*

Mean follow-up in both groups was comparable (>12 months, ranging from 6 – 46 months). Mean age on the day of surgery was 50.8 years (ranging from 40-63 years). Mean time after surgery, of the post-operative photos used in the evaluation, was 10.3 months (range: 8.5-11.6) in group A and 10.9 months (range: 8.6-11.9) in group B. Average results for group A and B are presented in Figures III to VI, respectively.



**Figure III.** Average result after MACS-lifting (group A).

*Pre- (A,C,E,G,I) and postoperative photographs (B,D,F,H,J). Patients' age was 42 years at the day of procedure, the post-operative photo was shot after seven months.*

Results of the analysis of the pre- and postoperative photographs by the panel members are shown in Table I. Both the plastic surgeons ( $p=0.009$ ) and medical students ( $p=0.01$ ) panels found significant improvements in zone 1 (tear trough/ nasojugal groove) following surgery in Group B (MACS with lipofilling) patients. The nasolabial fold (zone 2) did not show any significant difference in improvement between groups A and B in the frontal view (surgeons:  $p=0.664$ ; students;  $p=0.335$ ). In this region, the three-quarter view showed significant improvement only according to the medical student panel (students:  $p=0.003$ ; surgeons:  $p=0.10$ ). Lipofilling of the malar eminence (in three quarter view) improved results significantly as rated by both panels (surgeons:  $p=0.001$ ; students:  $p=0.007$ ).

Tabel I

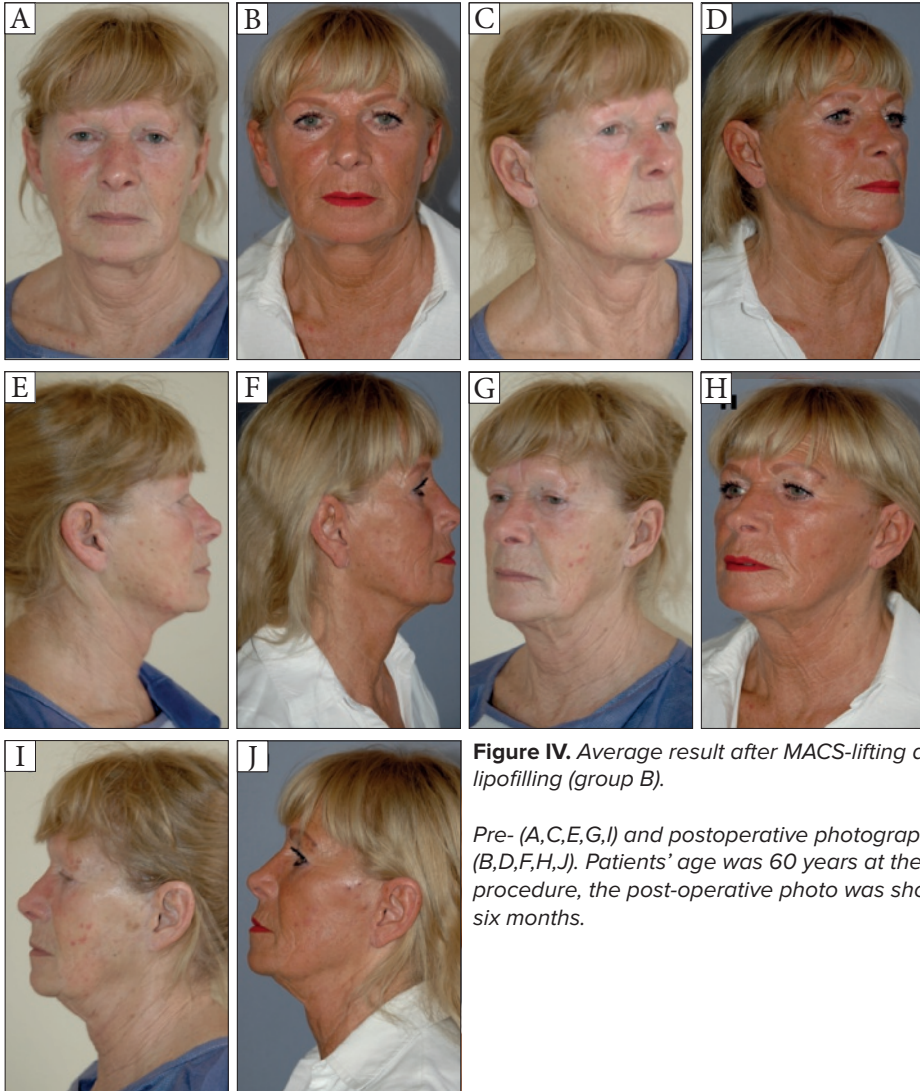Difference in standardized mean, and ( <i>P-value</i> ) group A vs. B	medical students plastic surgeons	
	Frontal photo view	
Zone 1	0,606 (0,009)*	0,505 (0,010)*
Zone 2	0,101 (0,664)	0,202 (0,335)
Three-quarter photo view		
Zone 2	0,447 (0,100)	0,591 (0,003)*
Zone 3	0,736 (0,001)*	0,577 (0,007)*

\* Significant

## Discussion

Optimal rejuvenating of the ageing face should involve repositioning of ptotic soft tissues as well as the correction of volume deficiency where present. Popularized by Coleman<sup>9</sup>, lipofilling is being increasingly used to augment soft tissues in aesthetic- and reconstructive plastic surgery<sup>19</sup>. The benefits of this technique include: a readily available source of permanent filler which is autologous, simultaneous body contouring in the process of fat harvesting, relative ease of execution<sup>20,21</sup>, negligible morbidity, low costs and importantly, predictable and reliable results can be obtained. In addition, unlike synthetic fillers, autologous fat has the ability to change with the patient and adverse reactions are extremely uncommon. Local improvements in skin quality<sup>22</sup> at graft location is another benefit of lipofilling and may add to a better postoperative result. Recent investigations on multipotent adipocyte derived stem cells may open up the possibility for thin patients to benefit from lipofilling also<sup>23-26</sup>.

In this study, statistically significant, lipofilling improved the tear trough and malar eminence. Surprisingly, filling of the nasolabial fold using a round tipped cannula did not yield consistent improvements. Previous studies on fat graft survival in the nasolabial crease have shown good results compared to other facial target zones<sup>5,27,28</sup> attributable to the rich vascularisation of the maxillofacial region. Pontius et al reported that lipofilling in the nasolabial crease was an effective adjunct in midface lifting<sup>2</sup>. Hypothesizing that our lack of effect might be a result from filling the nasolabial crease with a blunt cannula, we are currently investigating the value of pretreating this area with a sharper V-dissector instrument.



**Figure IV.** Average result after MACS-lifting and lipofilling (group B).

*Pre- (A,C,E,G,I) and postoperative photographs (B,D,F,H,J). Patients' age was 60 years at the day of procedure, the post-operative photo was shot after six months.*

Despite the increasing number of favorable aesthetic outcomes seen following lipofilling in the literature<sup>4</sup>, the technique is still often plagued with uncertainties about its longevity and the unpredictability of the survival of the fat cells<sup>21,29</sup>. Though post-operative graft atrophy has been reported elsewhere<sup>29,30</sup>, in this study no need for secondary lipofilling was observed during the period of investigation. Authors believe that centrifugation before injection improves reproducibility and allows for better quantification of volumes needed for injection. Most authors would agree that the viability of the fat cells is affected by the manner by which the cells are harvested and processed<sup>9,31-38</sup>, the rapidity and degree of revascularization of

the transplanted fat cells<sup>21,26,39</sup> and the degree of fibrosis in the transplanted area<sup>21,29,34,40,41</sup>. The follow-up period of 10.3 months in group A and 10.9 months in group B was found to be sufficient by the authors. Recent studies about fat cell survival<sup>134,42,43</sup> suggest that major changes in volume after 6 months are highly unlikely due to the degree of cell organization<sup>34,43</sup> and deep vascularisation<sup>34,43,44</sup> of the graft. Authors concur with Kaufman et al. for further objectifying graft survival in humans with modern volumetric imaging technology.

The use of autologous angiogenesis promoters such as autologous growth hormones derived from platelets (PDGF)<sup>45</sup>, vascular endothelial growth factor (VEGF)<sup>39,46</sup>, hypoxia-inducible factor 1 (HIF-1)<sup>29,47</sup>, and insulin-like growth factor (IGF-1)<sup>48,49</sup> have shown to be promising in their ability to improve the viability of the fat grafts<sup>44</sup>. These factors are released by platelets<sup>50</sup>, which can be added to the fat graft in the form of platelet rich plasma (PRP). It is possible that these new developments will improve short and long-term results with lipotransfer by accelerating vascular ingrowth<sup>43,51</sup>.

In this non-randomized retrospective study, all patients with loss of volume as a clear part of their ageing process were offered the option of adding lipofilling to MACS-lifting, during the first consultation. One could argue that results in this group were better due to the worsening pre-operative state (evident loss of volume). However in most cases, this loss will be more subtle and not as evident, but will still be a major contributing factor to the patients facial age. In the MACS lift only group, no doubt, there will be patients that would have had benefit from lipofilling also. We believe that in a larger group of patients than anticipated up to now, lipofilling will improve results. Defatta et al. drew similar conclusions in their study<sup>52</sup>.

This study, evaluating the objective aesthetic outcome in patients undergoing MACS lifting with or without lipofilling, demonstrates that lipofilling enhances aesthetic outcome of MACS-lifting for facial rejuvenation significantly.

## **Acknowledgements**

We would like to express our gratitude to all panel members, our statistician and the patients who completed the questionnaires for their contribution to this manuscript. Also we thank RL Luijendijk, MD, PhD, plastic surgeon, for his comments on the manuscript.

## References

- 1.Little JW. Applications of the classic dermal fat graft in primary and secondary facial rejuvenation. *Plastic and reconstructive surgery* 2002;109:788-804.
- 2.Pontius AT, Williams EF, 3rd. The evolution of midface rejuvenation: combining the midface-lift and fat transfer. *Arch Facial Plast Surg* 2006;8:300-5.
- 3.Trepasat F. Volumetric face lifting. *Plastic and reconstructive surgery* 2001;108:1358-70; discussion 71-9.
- 4.Meier JD, Glasgold RA, Glasgold MJ. Autologous fat grafting: long-term evidence of its efficacy in midfacial rejuvenation. *Arch Facial Plast Surg* 2009;11:24-8.
- 5.DeFatta RJ, Williams EF, 3rd. Evolution of midface rejuvenation. *Arch Facial Plast Surg* 2009;11:6-12.
- 6.Fitzgerald R, Graivier MH, Kane M, et al. Update on facial aging. *Aesthetic surgery journal / the American Society for Aesthetic Plastic surgery* 2010;30 Suppl:11S-24S.
- 7.Donofrio LM. Panfacial volume restoration with fat. *Dermatol Surg* 2005;31:1496-505.
- 8.Donofrio LM. Fat distribution: a morphologic study of the aging face. *Dermatol Surg* 2000;26:1107-12.
- 9.Coleman SR. Facial recontouring with lipostructure. *Clin Plast Surg* 1997;24:347-67.
- 10.Pessa JE. An algorithm of facial aging: verification of Lambros's theory by three-dimensional stereolithography, with reference to the pathogenesis of midfacial aging, scleral show, and the lateral suborbital trough deformity. *Plast Reconstr Surg* 2000;106:479-88; discussion 89-90.
- 11.Richard MJ, Morris C, Deen BF, Gray L, Woodward JA. Analysis of the anatomic changes of the aging facial skeleton using computer-assisted tomography. *Ophthalmic plastic and reconstructive surgery* 2009;25:382-6.
- 12.Lam SM. A new paradigm for the aging face. *Facial plastic surgery clinics of North America* 2010;18:1-6.
- 13.Besins T. The "R.A.R.E." technique (reverse and repositioning effect): the renaissance of the aging face and neck. *Aesthetic Plast Surg* 2004;28:127-42.
- 14.Guerrerosantos J. Evolution of technique: face and neck lifting and fat injections. *Clinics in plastic surgery* 2008;35:663-76, viii.
- 15.Tonnard P, Verpaele A, Monstrey S, et al. Minimal access cranial suspension lift: a modified S-lift. *Plast Reconstr Surg* 2002;109:2074-86.
- 16.Tonnard P, Verpaele A. The MACS-lift short scar rhytidectomy. *Aesthetic surgery journal / the American Society for Aesthetic Plastic surgery* 2007;27:188-98.
- 17.Fitzgerald R, Graivier MH, Kane M, et al. Surgical versus nonsurgical rejuvenation. *Aesthetic surgery journal / the American Society for Aesthetic Plastic surgery* 2010;30 Suppl:28S-30S.
- 18.Conde-Green A, Baptista LS, de Amorin NF, et al. Effects of centrifugation on cell composition and viability of aspirated adipose tissue processed for transplantation. *Aesthetic surgery journal / the American Society for Aesthetic Plastic surgery* 2010;30:249-55.
- 19.Clauser L, Polito J, Mandrioli S, Tieghi R, Denes SA, Galie M. Structural fat grafting in complex reconstructive surgery. *The Journal of craniofacial surgery* 2008;19:187-91.
- 20.Xie Y, Zheng DN, Li QF, et al. An integrated fat grafting technique for cosmetic facial contouring. *J Plast Reconstr Aesthet Surg* 2010;63:270-6.
- 21.Donofrio LM. Techniques in facial fat grafting. *Aesthetic surgery journal / the American Society for Aesthetic Plastic surgery* 2008;28:681-7.
- 22.Coleman SR. Structural fat grafting: more than a permanent filler. *Plastic and reconstructive surgery* 2006;118:108S-20S.
- 23.Zuk PA, Zhu M, Ashjian P, et al. Human adipose tissue is a source of multipotent stem cells. *Mol Biol Cell* 2002;13:4279-95.
- 24.Strem BM, Hicok KC, Zhu M, et al. Multipotential differentiation of adipose tissue-derived stem cells. *Keio J Med* 2005;54:132-41.
- 25.De Ugarte DA, Ashjian PH, Elbarbary A, Hedrick MH. Future of fat as raw material for tissue regeneration. *Ann Plast Surg* 2003;50:215-9.
- 26.Tanzi MC, Fare S. Adipose tissue engineering: state of the art, recent advances and innovative approaches. *Expert Rev Med Devices* 2009;6:533-51.
- 27.Cook T, Nakra T, Shorr N, Douglas RS. Facial recontouring with autogenous fat. *Facial Plast Surg* 2004;20:145-7.
- 28.Eremia S, Newman N. Long-term follow-up after autologous fat grafting: analysis of results from 116

- patients followed at least 12 months after receiving the last of a minimum of two treatments. *Dermatol Surg* 2000;26:1150-8.
- 29.Kaufman MR, Miller TA, Huang C, et al. Autologous fat transfer for facial recontouring: is there science behind the art? *Plast Reconstr Surg* 2007;119:2287-96.
- 30.Ersek RA. Transplantation of purified autologous fat: a 3-year follow-up is disappointing. *Plast Reconstr Surg* 1991;87:219-27; discussion 28.
- 31.Bertossi D, Zancanaro C, Trevisiol L, Albanese M, Ferrari F, Nocini PF. Lipofilling of the lips: ultrastructural evaluation by transmission electron microscopy of injected adipose tissue. *Arch Facial Plast Surg* 2003;5:392-8.
- 32.Tzikas TL. Lipografting: autologous fat grafting for total facial rejuvenation. *Facial Plast Surg* 2004;20:135-43.
- 33.Jackson IT, Simman R, Tholen R, DiNick VD. A successful long-term method of fat grafting: recontouring of a large subcutaneous postradiation thigh defect with autologous fat transplantation. *Aesthetic Plast Surg* 2001;25:165-9.
- 34.Brucker M, Sati S, Spangenberger A, Weinzweig J. Long-term fate of transplanted autologous fat in a novel rabbit facial model. *Plast Reconstr Surg* 2008;122:749-54.
- 35.Gonzalez AM, Lobocki C, Kelly CP, Jackson IT. An alternative method for harvest and processing fat grafts: an in vitro study of cell viability and survival. *Plast Reconstr Surg* 2007;120:285-94.
- 36.Pu LL, Coleman SR, Cui X, Ferguson RE, Jr., Vasconez HC. Autologous fat grafts harvested and refined by the Coleman technique: a comparative study. *Plast Reconstr Surg* 2008;122:932-7.
- 37.Conde-Green A, Baptista LS, de Amorin NF, et al. Effects of centrifugation on cell composition and viability of aspirated adipose tissue processed for transplantation. *Aesthet Surg J*;30:249-55.
- 38.Piasecki JH, Gutowski KA, Moreno KM, Lahvis GL. Purified viable fat suspended in matrigel improves volume longevity. *Aesthet Surg J* 2008;28:24-32.
- 39.Yamaguchi M, Matsumoto F, Bujo H, et al. Revascularization determines volume retention and gene expression by fat grafts in mice. *Exp Biol Med (Maywood)* 2005;230:742-8.
- 40.Sommer B, Sattler G. Current concepts of fat graft survival: histology of aspirated adipose tissue and review of the literature. *Dermatol Surg* 2000;26:1159-66.
- 41.Hwang K, Han JY, Kim DJ. Dermofat graft in deep nasolabial fold and facial rhytidectomy. *Aesthetic plastic surgery* 2003;27:254-7.
- 42.Guijarro-Martinez R, Alba LM, Mateo MM, Torres MP, Pascual Gil JV. Autologous fat transfer to the cranio-maxillofacial region: updates and controversies. *J Craniomaxillofac Surg* 2010
- 43.Pires Fraga MF, Nishio RT, Ishikawa RS, Perin LF, Jr AH, Malheiros CA. Increased survival of free fat grafts with platelet-rich plasma in rabbits. *J Plast Reconstr Aesthet Surg* 2010.
- 44.Nakamura S, Ishihara M, Takikawa M, et al. Platelet-rich plasma (PRP) promotes survival of fat-grafts in rats. *Annals of plastic surgery* 2010;65:101-6.
- 45.Eppley BL, Pietrzak WS, Blanton M. Platelet-rich plasma: a review of biology and applications in plastic surgery. *Plastic and reconstructive surgery* 2006;118:147e-59e.
- 46.Nishimura T, Hashimoto H, Nakanishi I, Furukawa M. Microvascular angiogenesis and apoptosis in the survival of free fat grafts. *Laryngoscope* 2000;110:1333-8.
- 47.Hausman GJ, Richardson RL. Adipose tissue angiogenesis. *J Anim Sci* 2004;82:925-34.
- 48.Yuksel E, Weinfeld AB, Cleek R, et al. Increased free fat-graft survival with the long-term, local delivery of insulin, insulin-like growth factor-I, and basic fibroblast growth factor by PLGA/PEG microspheres. *Plast Reconstr Surg* 2000;105:1712-20.
- 49.Hong SJ, Lee JH, Hong SM, Park CH. Enhancing the viability of fat grafts using new transfer medium containing insulin and beta-fibroblast growth factor in autologous fat transplantation. *J Plast Reconstr Aesthet Surg* 2009.
- 50.El-Sharkawy H, Kantarci A, Deady J, et al. Platelet-rich plasma: growth factors and pro- and anti-inflammatory properties. *Journal of periodontology* 2007;78:661-9.
- 51.Por YC, Yeow VK, Louri N, Lim TK, Kee I, Song IC. Platelet-rich plasma has no effect on increasing free fat graft survival in the nude mouse. *J Plast Reconstr Aesthet Surg* 2009;62:1030-4.
- 52.DeFatta RJ, Williams EF, 3rd. Fat transfer in conjunction with facial rejuvenation procedures. *Facial plastic surgery clinics of North America* 2008;16:383-90, v.






---

---

# III

## THE EFFECTS OF PLATELET RICH PLASMA ON RECOVERY TIME AND AESTHETIC OUTCOME IN FACIAL REJUVENATION: PRELIMINARY RETROSPECTIVE OBSERVATIONS

- 
1. JOEP C.N. WILLEMSSEN
  2. BEREND VAN DER LEI
  3. KARIN M. VERMEULEN
  4. HIERONYMUS P.J.D. STEVENS

### *Introduction*

This paper focuses on the possible effect of PRP (Platelet Rich Plasma) on recovery time and aesthetic outcome after facial rejuvenation. We conducted a retrospective analysis with regard to recovery time and the aesthetic improvement after treatment among four groups of patients: a group of patients treated with fat grafting only (Group I), a group of patients treated with fat grafting with PRP (Group II), a group of patients treated with MACS lift and fat grafting (Group III) and a group of patients treated with MACS lift, fat grafting and PRP (Group IV).

### *Results*

The addition of PRP resulted in a significant drop in the number of days returning to work/restart of social activities when added to a lipofilling procedure (Group I: no PRP 18.9 days versus Group II: PRP 13.2 days,  $p=0.019$ ). The effect seemed absent when added to a MACS-lifting lipofilling procedure. Also, the aesthetic outcome of the lipofilling and MACS-lift lipofilling groups that received PRP (Groups II and IV) was significantly better than the groups without PRP (Groups I and III).

### *Material and Methods*

For the first part of this study, evaluating recovery time after surgery, the following selection criteria were used: Non-smoking females, aged 35-65 years, with a complete documented follow up. In total, 82 patients were included to evaluate patient reported recovery time.

For the second part of the study, evaluating potential differences in aesthetic outcome, records of these 82 patients were additionally screened for the presence of pre- and postoperative standardized photographs in three views (AP, Lateral, Oblique), leaving 37 patients to evaluate. A questionnaire was developed to evaluate the aesthetic outcome in all four groups of patients. This questionnaire was used in an expert panel that consisted of 10 plastic surgeons.

### *Conclusion*

Adding PRP to facial lipofilling reduces recovery time and improves the overall aesthetic outcome in MACS lifting.

## Introduction

Since the first transfer of autologous fat as de-epithelialised dermofascial graft in the 1890s and as injectable graft in the 1920s<sup>1</sup>, it took more than 80 years before autologous fat grafting techniques were used on a regular base in facial rejuvenation: nowadays, it is used in addition to lifting procedures to improve the specific signs of facial aging related to loss of volume<sup>2,3</sup>. Unpredictability of the amount of fat graft take and to a certain amount limited fat graft survival after lipofilling has been described<sup>4</sup> and is still a subject for debate<sup>4,7</sup>. Several factors may play a role in fat graft take, such as the harvesting technique<sup>8</sup>, the method used for processing the harvested fat<sup>9</sup> and the technique of fat injection<sup>10</sup>. Also the vascularization of the receptor area seems to be of significant relevance<sup>11</sup>.

Several studies have demonstrated that fat graft take may significantly increase with the additional use of Platelet Rich Plasma (PRP) extracted from whole blood<sup>12,13</sup> and that PRP may enhance wound healing and thereby speed up recovery time<sup>14-16</sup>. Moreover, PRP by itself might additionally improve the quality of the skin by increasing elasticity<sup>17,18</sup>.

Since 2010 we routinely use PRP in facial rejuvenation procedures. We clearly had the impression the additional use of PRP significantly reduces recovery time and enhances the aesthetic outcome. In order to elucidate these effects, this retrospective study with regard to recovery time and aesthetic outcome was undertaken in the following groups of patients: a group of patients treated with fat grafting only (Group I), a group of patients treated with fat grafting with PRP (Group II), a group of patients treated with MACS lift and fat grafting (Group III) and a group of patients treated with MACS lift, fat grafting and PRP (Group IV).

## Material & methods

### *Patient selection*

All cases have been operated between 2008 and 2012 in Bergman Clinics The Hague by the senior author. In cases where loss of volume was the major contributing factor of facial aging lipofilling was performed. In cases where also significant ptosis and subsequent descent of tissues was observed, lipofilling was combined with MACS-lifting. Since the introduction of PRP in 2010, subsequently all cases where lipofilling was used were treated with PRP simultaneously. As a result a consecutive series of patients could be analyzed without any bias for the use of PRP.

### *Evaluation of recovery time and aesthetic outcome*

For evaluating recovery time after surgery, the following selection criteria were used: Non-smoking females, aged 35-65 years, who underwent lipofilling of the face with or without a MACS-lift, with or without the addition of PRP and with a complete documented follow up (including a completed standardized survey that was sent automatically to all patients 4 week after the procedure including questions regarding recovery time). In total, patient reported recovery time was evaluated in 82 patients. Recovery time was defined by the number of days that passed before patients considered themselves capable to return to work or to restart social activities.

For evaluation of the aesthetic outcome, records of these 82 patients were additionally screened for the presence of pre- and postoperative standardized photographs in three views (AP, Lateral, Oblique). Photos were taken during their regular 3-month follow-up appointment, leaving 37 patients for evaluation. All photographs were cropped with the analyzed area

placed on uniform colored background; obviously photos were not edited in any way that could interfere with interpretation. The anterior-posterior photographs were performed in the Francoforte plan, mimicking anatomical skull position.

A questionnaire was developed (based on several existing surveys<sup>19-21</sup>) to evaluate the aesthetic outcome in all four groups of patients by an expert panel that consisted of 10 plastic surgeons with experience in the field of facial aesthetic surgery. Members of the expert panel had not operated any of the included patients. Each page of the questionnaire contained the pre- or postoperative standardized photographs of just one patient in the three views mentioned (AnteroPosterior, (AP) Lateral (Lat), Oblique (Oblq)) and four questions. Questions one to three were scored by using a visual analogue scale. This scale ranged from 0 to 10 with lower scores representing a lower aesthetic result (Table II). A total of 74 pages were constructed in this fashion. All photographs and questions were placed in a digital environment. Page order was randomized, mixing groups and pre- and postoperative pages and procedures throughout the survey. No postoperative page succeeded or preceded a preoperative page of the same patient and no information was given to the panel whether a page was pre- or postoperative or what procedure had been used

### *MACS-lift*

MACS lifting was performed as described by Tonnard and Verpaele<sup>22</sup> with some minor modifications. A 3-lobbed pre-trageal incision was used (instead of a retrotrageal incision), subsequently running vertically upward into the sideburn (instead of running in front of the side burn). Subcutaneous dissection was extended 1-2 cm anterior to the border of the parotic gland and extended four cm under the angle of the Mandibule, revealing the Platysma muscle clearly. One centimeter cranial to the helical root, a pretrageal purse-string suture was anchored to the deep temporalis fascia. Incorporating the SMAS overlying the parotid gland this first purse-string suture runs inferiorly in a narrow U-shape well beyond the angle of the mandible including the Platysma muscle firmly, before returning to the starting point one cm anterior to the first leg of the suture. In this fashion the suture uses the angle of the mandible as a pulley, resulting in a more pronounced effect on the floor of the mouth when tied. The second purse-string suture started from the same anchoring point running anterior to the first loop making its turn at the level of the retaining ligaments just above the jowling.

### *Lipofilling or micro fat grafting*

The Coleman technique<sup>23, 24</sup> for fat harvesting and injection was used but refined by using a smaller custom made canula for harvesting (inner diameter 1.3 mm). The donor sites for harvesting were the upper legs in all patients. Approximately 3 times more fat was harvested than the estimated amount required for the procedure. Fat was centrifuged for 2,5 minutes at the maximum speed of 3000RPM (IEC MediSpin Centrifuge), after which the oily fraction (top layer) and liquid waste (infiltrate, blood: bottom layer) were drained away, preserving the pre-adipocyte-rich pellet<sup>9</sup>. Fat injection was performed using a short curved Coleman cannula by which droplets were evenly injected in a 3 dimensional space. Between 13 to 23 cc of fat were injected both in superficial as well as deeper planes in each side of the face. Superficial injection was performed in the temporal region (above the superficial temporal fascia for reasons of vascularization), crowfeet area, and anterior part of the cheek (to allow for direct support of the skin in the latter two zones mentioned). Injection in deeper planes was performed in the malar eminence, SOOF, tear trough, central part of the mid face, the nasolabial folds and the marionette folds. Injection here was predominantly performed to recreate curves and or

projection in the face. Injection in the lips and upper eyelid was performed on indication only.

### *PRP preparation*

27 cc whole blood of the patient was introduced in the Biomet GPS-III© device (after adding 3cc of citrate to prevent clotting). 15 Minutes of centrifugation at 3000 rpm allowed for gravitational separation of the whole blood into its three fractions: erythrocytes, Platelet Poor Plasma (PPP) and Platelet Rich Plasma (PRP). A total of 3 cc of PRP was yielded in this fashion. The PRP was activated by adding 0.45 cc of CaCl<sub>2</sub> (10%, matching 15-volume % Ca<sup>2+</sup>), 1 minute prior to injection. 3 cc of PPP were used as tissue glue in MACS-lifting by irrigating the pocket. In all other cases PPP was not used.

After PRP activation, the 3cc of PRP + 0.45 cc of CaCl<sub>2</sub> was injected into the lipofilling planes, transcutaneously in small aliquots in a standardized fashion. 1.7 cc was used per side of the face. With an average amount of 15 cc of fat per side the PRP fat mix-ratio was around 1:10.

### *Statistics*

All statistic tests were performed under supervision of a senior statistician. Descriptive statistics were used to evaluate the population's mean age and SD at time of operation. Recovery time was defined as the number of days returning to work or restart the social activities. A mean number of days was calculated for every group and compared using an independent T-test (Table I).

To determine aesthetic improvement and gain after the procedure, scores assigned to the pre-operative pages were subtracted from the post-operative pages (Table II). A mean and median number of points gained after the procedure assigned by the 10-blinded observers was calculated for every group. A Mann-Whitney U (2-tailed exact) was used to test for significant differences. Data from the patients records and survey was analyzed using SPSS (IBM inc, Chicago,IL).

## **Results**

Of the 82 patients enrolled in this study, 25 patients underwent lipofilling without PRP (Group I), 18 lipofilling with PRP (Group II). 17 Patients received a MACS-lifting with lipofilling without PRP (Group III) and 22 were treated by MACS-lifting with lipofilling and PRP (Group IV). No significant differences in patients' age existed among the groups when evaluating recovery as well as aesthetic outcome, and no significant difference existed between the observer assigned pre-operative mean aesthetic scores when comparing group I versus group II, and group III versus group IV.

Patients that underwent lipofilling with PRP reported a significant lower number of days to return to work/restart social activities (Group I: no PRP 18.9 days versus Group II:PRP 13.2 days,  $p=0.019$ ; see Table I). In patients that underwent a MACS-lifting with lipofilling with or without PRP the effect was less distinct: return to work/restart social activities was an average of 18.7 days without PRP (Group III) versus. 17.5 days when PRP (Group IV) was used ( $p= 0.424$ ).

When PRP was added to a lipofilling procedure the patients improved significantly more than from a lipofilling procedure without PRP (see Table II). With the first question, appearance regarding the patients' age, the PRP group improved significantly more: no PRP: 1.211 vs. PRP: 1.580 points gained ( $p=0.039$ ). Question 2, appearance disregarding the patients' age,

showed more improvement, but not a significant one: No PRP: 1.355 vs. PRP: 1.910 points gained ( $p=0.536$ ). Question 3, regarding facial volume, again showed a significant difference: No PRP: 1.644 vs. PRP: 1.740 points gained ( $p<0.01$ ).

The addition of PRP also improved the results after a MACS-lifting plus lipofilling procedure. Question 1 and 2 showed significantly more improvement: Question 1: No PRP: 0.887 vs. PRP 1.580 points gained ( $p<0.01$ ) and Question 2: No PRP: 1.137 vs. PRP 1.910 points gained ( $p=0.019$ ). Question 3, regarding facial volume, the PRP group again showed more improvement, but this results was not significant: No PRP: 1.550 vs. PRP 1.740 points gained ( $p= 0.553$ ). Average results are presented in Figures I and II.

Table I: Recovery time\*

Lipofilling	Group I (PRP-)	Group II (PRP+)	p**
	Mean (SD)	Mean (SD)	
-RTW/social activities	18.9 (8.5)	13.2 (6.4)	0.019
MACS + Lipofilling	Group III (PRP-)	Group IV (PRP +)	p**
	Mean (SD)	Mean (SD)	
-RTW/social activities	18.7 (9.2)	17.5 (10.9)	0.424

\*Recovery time was defined as the patient reported number of days after surgery returning to work (RTW)/social activities

\*\*Independent sampels t-test

## Discussion

Our retrospective analysis demonstrates that PRP improves the overall outcome of either lipofilling or a MACS lift combined with lipofilling in facial rejuvenation, both in recovery time as well as with regard to aesthetic outcome. Whether this is due to improved fat graft take or to an intrinsic rejuvenation effect of the PRP still has to be elucidated.

Thus far, the number of studies that have used quantitative analyses as outcome variables for recovery to assess the effect of PRP is limited. In case any beneficial effect of PRP is mentioned in literature (in relation to e.g. tendon repair, fat graft survival or increased bone density) it usually refers to the end result after healing is complete, not to recovery time itself. The study of Na et al.<sup>14</sup> demonstrated a significant reduction in post-operative recovery time and improved healing after fractional carbon dioxide laser resurfacing treatment to the inner arms when combined with PRP injection in the laser treated area. These findings are supported by the study of Lee et al.<sup>15</sup> They showed in a “split face trial” that when using fractional carbon dioxide laser resurfacing for treatment of facial acne scars, a significant reduction in erythema, and a faster clinical recovery rate could be achieved when adding PRP to the wound area.

Accelerated wound healing and thereby reduced recovery time when adding PRP to the lipograft might be explained by the addition of a significantly increased amount of platelet derived growth factors. These growth factors trigger homing, migration, proliferation and differentiation of a wide variety of cells<sup>16, 25</sup>. In tendon repair, it has been demonstrated that

the local inflammatory response is significantly increased when PRP is added<sup>26</sup>. In addition, a higher number local inflammatory cell could speed up clearance of cellular debris, hematoma and even bacteria; factors that greatly influence the process of wound healing, including its duration

The addition of PRP made a significant impact on the recovery time of the patients that received lipofilling only. This effect seems to be absent when lipofilling is combined with a MACS-lifting. This finding might be explained by the fact that the PRP was injected only in the areas where lipofilling was performed and not in the areas of the dissection of the lifting procedure. Also the extended dissection of the MACS-lift results in a significantly larger trauma area (thus variation in recovery) then the lipofilling part of the procedure, possibly masking the effect of the PRP.

Results from this study further support that lipofilling is an effective treatment option in facial rejuvenation, as based on our photographic evaluation. The effect is probably caused by adding volume and reshaping of curves and contour of the face (Question 3, Table II).

**Table II: Aesthetic outcome**

Lipofilling	No PRP (n=9)			PRP (n=10)			(sig.)*
	Mean	Median	Mean rank	Mean	Median	Mean rank	
-Q1	1.211	1	87.02	1.580	1	103.14	(0.039)
-Q2	1.355	1	92.93	1.910	1	97.82	(0.536)
-Q3	1.644	1	83.23	1.740	2	106.65	(0.003)

MACS + Lipofilling	No PRP (n=8)			PRP (n=10)			(sig.)*
	Mean	Median	Mean rank	Mean	Median	Mean rank	
-Q1	0.887	1	78.19	1.580	1	100.35	(0.004)
-Q2	1.137	1	80.49	1.910	1	98.51	(0.019)
-Q3	1.550	1	87.94	1.740	2	92.55	(0.553)

Q1: Taking the patient's age into account: How would you assess the appearance of this face? (on a scale from 1-10, 1: much older for age -- 5: according to age -- 10: much younger for age)

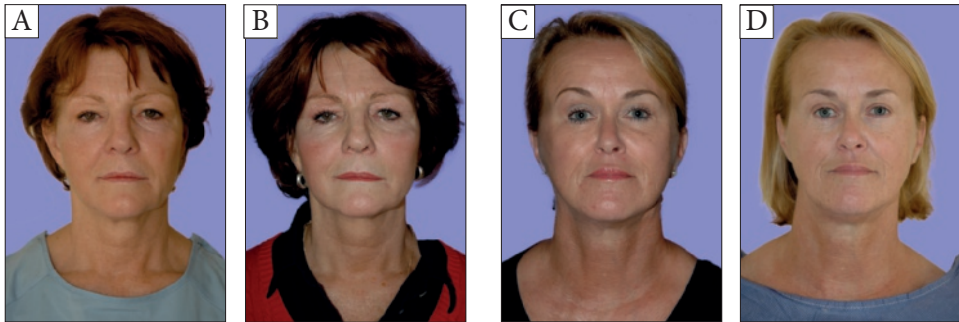Q2: NOT taking age into account: How would you assess the appearance of this face? (on a scale from 1-10, 1: very many signs of aging -- 10: no signs of aging)

Q3: NOT taking age into account: How would you assess facial volume of the patient? (on a scale from 1-10, 1: most profound loss of volume -- 10: No loss of volume)

\* Mann-Whitney U test using median, 2-tailed exact



Although the follow-up of this study is relatively short, authors believe that the change in volume, as confirmed to be present by our panel members in their subjective evaluation, is of relevance.



**Figure I and II.** Average results after a MACS-lift with lipofilling and PRP. A 52-year old female before (A) and 3 months after (B) surgery, and A 48-year old female after a lipofilling with PRP procedure, before (C) and 3 months after (D) surgery.

The study of Nishimura et al.<sup>27</sup> showed that in case there is fat graft necrosis, it will peak around 30 days. Initiation of vascular ingrowth was seen around 7 days, making further significant resorption unlikely after 60 days of follow-up. Further supporting facts are found in the well-conducted mice study of Thanik et al.<sup>28</sup> using human fat. They reported that 82% of graft volume was, as they described 'viable and vascularized' after 8 weeks.

Our results in addition show that adding PRP improves the outcome of facial rejuvenation even further than lipofilling does alone. This might be due to an improved angiogenesis pathway and formation of new capillaries, enhancing the viability of the injected fat cells possibly even allowing for better regeneration. This idea is supported by some fundamental animal studies demonstrating improved graft take when using PRP<sup>12, 13, 29, 30</sup>. A higher number of viable adipocytes and infiltrating blood vessel was found in all these studies. Although the exact underlying mechanism of the findings are still unknown, the improved graft take might be due to a higher number of surviving ADSC's (Adipose derived stem cell): the study of Fukaya et al. showed that PRP can inhibit apoptosis of these cells by reducing DAPK1 and BIM mRNA expression<sup>31</sup>. Fat grafts enriched with ADSC's show a higher graft take<sup>32</sup>, emphasizing the important role of this cell in graft survival. Also, according to the in vitro study of Rophael et al., the mix of growth factors in PRP changes the late differentiation of the ADSC, inducing late de novo adipogenesis<sup>33</sup>, which might also contribute to end graft volume.

Platelet rich plasma by itself might also be responsible for the effect of facial rejuvenation. Michalevicz et al.<sup>34</sup>, found that vascular muscle cells require mitogens such as PDGF to proliferate and proved that PDGF is one of the most potent mitogenic factors present in the human serum<sup>35</sup>. PDGF might not only enhance the process of inflammation and angiogenesis but also helps in improving skin quality and texture through collagen synthesis and formation. Patil et al.<sup>36</sup> found that collagen synthesis in human is critically dependent on the extracellular environment and is dose dependent on pro-collagenase gene expression especially for the synthesis of type II collagen. Several studies show skin improvement after direct cutaneous injection of PRP<sup>17, 37</sup>. Prospective studies with only PRP, only fat and a combination of both might further elucidate the underlying mechanism.

In conclusion, this study clearly demonstrates that adding PRP in facial rejuvenation reduces recovery time after lipofilling and improves the overall aesthetic outcome of both lipofilling and MACS-lifting combined with lipofilling. Both effects might be due to either improved fat graft take or to an intrinsic rejuvenation effect of the PRP. However, it remains uncertain what the influence is of different methods of fat harvesting, processing and injection of the fat; all of these aspects will have their own special effect on fat graft survival<sup>9,10</sup> and thereby may contribute to the variation in the final result.

## **Study limitations**

Due to the fact that this study was performed retrospectively, all subjects appeared for their postoperative evaluation with their normal make-up on, not being informed prior to the postoperative appointment that any photographs taken would be used for statistical analysis. For this reason, authors believe no bias was introduced by the fact that all included subjects had some makeup on in their postoperative photographs. As the panel members evaluating the photographs were not informed about this finding they remained blinded (statistically speaking). The fact that pre-and postoperative photographs were placed randomly throughout the survey will further have dampened any limitation in this respect.

Conflict of Interest: None

Funding: None

## References

1. Holländer E. Handbuch der kosmetik. Leipzig: Veit & Comp.; 1912.
2. Willemsen JC, Mulder KM, Stevens HP. Lipofilling with minimal access cranial suspension lifting for enhanced rejuvenation. *Aesthetic surgery journal / the American Society for Aesthetic Plastic surgery*. 2011;31:759-69.
3. DeFatta RJ, Williams EF,3rd. Fat transfer in conjunction with facial rejuvenation procedures. *Facial plastic surgery clinics of North America*. 2008;16:383-90, v.
4. Kaufman MR, Miller TA, Huang C et al. Autologous fat transfer for facial recontouring: Is there science behind the art?. *Plastic and reconstructive surgery*. 2007;119:2287-96.
5. Pontius AT, Williams EF,3rd. The evolution of midface rejuvenation: Combining the midface-lift and fat transfer. *Arch Facial Plast Surg*. 2006;8:300-5.
6. Sommer B, Sattler G. Current concepts of fat graft survival: Histology of aspirated adipose tissue and review of the literature. *Dermatol Surg*. 2000;26:1159-66.
7. Guijarro-Martinez R, Alba LM, Mateo MM, Torres MP, Pascual Gil JV. Autologous fat transfer to the cranio-maxillofacial region: Updates and controversies. *J Craniomaxillofac Surg*. 2010.
8. Conde-Green A, de Amorim NF, Pitanguy I. Influence of decantation, washing and centrifugation on adipocyte and mesenchymal stem cell content of aspirated adipose tissue: A comparative study. *J Plast Reconstr Aesthet Surg*. 2010;63:1375-1381.
9. Conde-Green A, Baptista LS, de Amorin NF et al. Effects of centrifugation on cell composition and viability of aspirated adipose tissue processed for transplantation. *Aesthetic surgery journal / the American Society for Aesthetic Plastic surgery*. 2010;30:249-55.
10. Pu LL. Towards more rationalized approach to autologous fat grafting. *Journal of plastic, reconstructive & aesthetic surgery : JPRAS*. 2012;65:413-9.
11. Yamaguchi M, Matsumoto F, Bujo H et al. Revascularization determines volume retention and gene expression by fat grafts in mice. *Experimental biology and medicine (Maywood, N J)*. 2005;230:742-8.
12. Nakamura S, Ishihara M, Takikawa M et al. Platelet-rich plasma (PRP) promotes survival of fat-grafts in rats. *Annals of plastic surgery*. 2010;65:101-6.
13. Pires Fraga MF, Nishio RT, Ishikawa RS, Perin LF, Jr AH, Malheiros CA. Increased survival of free fat grafts with platelet-rich plasma in rabbits. *J Plast Reconstr Aesthet Surg*. 2010.
14. Na JI, Choi JW, Choi HR et al. Rapid healing and reduced erythema after ablative fractional carbon dioxide laser resurfacing combined with the application of autologous platelet-rich plasma. *Dermatologic surgery : official publication for American Society for Dermatologic Surgery [et al ]*. 2011;37:463-8.
15. Lee JW, Kim BJ, Kim MN, Mun SK. The efficacy of autologous platelet rich plasma combined with ablative carbon dioxide fractional resurfacing for acne scars: A simultaneous split-face trial. *Dermatologic surgery : official publication for American Society for Dermatologic Surgery [et al ]*. 2011;37:931-8.
16. Nikolidakis D, Jansen JA. The biology of platelet-rich plasma and its application in oral surgery: Literature review. *Tissue engineering*. 2008;14:249-58.
17. Ono I. A study on the alterations in skin viscoelasticity before and after an intradermal administration of growth factor. *Journal of cutaneous and aesthetic surgery*. 2011;4:98-104.
18. Redaelli A, Romano D, Marciano A. Face and neck revitalization with platelet-rich plasma (PRP): Clinical outcome in a series of 23 consecutively treated patients. *J Drugs Dermatol*. 2010;9:466-72.
19. Alsarraf R, F. LW,Jr, Anderson S, Murakami CS, M. JC,Jr. Measuring cosmetic facial plastic surgery outcomes: A pilot study. *Archives of facial plastic surgery : official publication for the American Academy of Facial Plastic and Reconstructive Surgery, Inc and the International Federation of Facial Plastic Surgery Societies*. 2001;3:198-201.
20. Swanson E. Objective assessment of change in apparent age after facial rejuvenation surgery. *Journal of plastic, reconstructive & aesthetic surgery : JPRAS*. 2011;64:1124-31.
21. Moolenburgh SE, Mureau MA, Hofer SO. Aesthetic outcome after nasal reconstruction: Patient versus panel perception. *Journal of plastic, reconstructive & aesthetic surgery : JPRAS*. 2008;61:1459-64.
22. Tonnard P, Verpaele A, Monstrey S et al. Minimal access cranial suspension lift: A modified S-lift. *Plastic and reconstructive surgery*. 2002;109:2074-86.

23. Fitzgerald R, Graivier MH, Kane M et al. Update on facial aging. *Aesthetic surgery journal / the American Society for Aesthetic Plastic surgery*. 2010;30 Suppl:11S-24S.
24. Coleman SR. Facial recontouring with lipostructure. *Clinics in plastic surgery*. 1997;24:347-67.
25. El-Sharkawy H, Kantarci A, Deady J et al. Platelet-rich plasma: Growth factors and pro- and anti-inflammatory properties. *Journal of periodontology*. 2007;78:661-9.



---

---

# IV

## THE ADDITION OF PRP TO FACIAL LIPOFILLING: A DOUBLE-BLIND PLACEBO-CONTROLLED RANDOMIZED TRIAL

- 
1. JOEP C.N. WILLEMSSEN
  2. JORIS VAN DONGEN
  3. MAROESJKA SPIEKMAN
  4. KARIN M. VERMEULEN
  5. MARTIN C. HARMSSEN
  6. BEREND VAN DER LEI
  7. HIERONYMUS P.J.D. STEVENS

### *Introduction*

Lipofilling is a treatment modality to restore tissue volume, but may also rejuvenate the aging skin. Platelet-rich plasma has been reported to augment the efficacy of lipofilling, both on graft take and rejuvenation by altering the ADSC. Authors hypothesized that PRP addition would increase the rejuvenating effect while shortening recovery time.

### *Results*

PRP did not improve the outcome of facial lipofilling when looking at skin elasticity improvement, graft volume maintenance in the nasolabial fold or patient satisfaction. Patient recovery after surgery however, dropped significantly. Furthermore, no skin rejuvenation effects from lipofilling could be observed.

### *Material and Methods*

The study conducted was a single-centre, double blinded, placebo-controlled randomized trial (2012-2015). In total, a well-defined cohort of 32 healthy females enrolled in the study, with 25 completing the follow-up. All patients underwent aesthetic facial lipofilling with either saline or PRP added. Outcome was determined by changes in skin elasticity, volumetric changes of the nasolabial fold, recovery time and patient satisfaction during follow-up (1 year).

### *Conclusion*

This study clearly demonstrates that the addition of PRP to the lipograft significantly reduces patient's reported recovery time, but does not significantly improve skin elasticity, volume retention nor overall patient satisfaction as compared to lipofilling alone. Moreover, reported effects of 'normal' (not SVF/ADSC enriched) lipofilling on skin rejuvenation, as has been reported and suggested to be seen in clinical studies when used in combination with facelift surgery, could also not be addressed.

## Introduction

Lipofilling, i.e. autologous fat transplantation or fat grafting, has become an important treatment modality in facial rejuvenation procedures: it is a safe procedure that requires only limited additional operating time. The presence of ASCs (Adipose stem Cells) in the lipograft 1 could result in tissue regeneration<sup>2-4</sup>. This has resulted in a paradigm shift towards the combination of facial rejuvenation by using both surgical lifting techniques as well as lipofilling procedures to restore both volume<sup>5, 6</sup> and tissue damage on a cellular level. By this combination of both surgical lifting and lipofilling, effects of gravity, loss of skin elasticity due to elastin degradation, loss of volume due to fat atrophy and bone resorption<sup>7, 8</sup> are all well addressed.

Fat grafting not only restores volume; it is also attributes to regeneration processes that become apparent by improved surface structure and tissue elasticity<sup>9</sup>. Nature's own regenerative source of wound healing is clot formation after platelet aggregation, homing of the cells involved in repair and fibronogenesis. Another reliable manner to produce injectable clots is the generation of platelet-rich plasma (PRP) and to use that to augment wound healing. PRP both serves as an instant scaffold for regeneration as well as a rich source of pro-regenerative growth factors<sup>10</sup>.

With extensive experience of the use of PRP as an additive to facial lipofilling procedures in our clinic dating back to 2005, retrospective analysis revealed several significant beneficial effects when adding PRP to the lipograft 11. We hypothesized that the addition of PRP to lipografts would augment tissue regeneration. This hypothesis was subsequently tested in this double-blind randomized placebo-controlled clinical trial for facial lipofilling.

## Methods

### *Study overview*

The study conducted was a single-centre, patient and investigator blinded, placebo-controlled trial undertaken at Bergman Clinics The Hague, the Netherlands. A flow-chart overview of the study is shown in Fig. 1. Patients' follow-up was 12 months in order to obtain long-term lasting results.

The study protocol complied with the Declaration of Helsinki and was approved by local medical ethics committee Zuid-west Holland (National legislator trial code: NL35142.098.11, local METC code: 12-014). All patients provided written informed consent.

### *Patient population and randomization*

Prior to inclusion, a power calculation was performed based on the limited available published data at that time. Following this calculation, aim was to include 32 subjects that would receive facial lipofilling in this study, with one half of the population receiving PRP, the other half a placebo (sterile saline), serving as control group. A detailed description of the randomization process is available online. Inclusion- exclusion criteria were strict, and are listed in Fig. 1.

The primary outcome of the study was skin elasticity improvement (R7 parameter measured by the MPA580 device) on predetermined fixed measurement locations (see Fig. 2) overlaying the area of intervention. Secondary outcome parameters of the study were: other changes in skin characteristics (R5-R6 parameters, MPA850, same locations), graft take (nasolabial fold decrease) and patient questionnaires regarding recovery time and satisfaction.

Patient enrollment in the study started in 2012 and ended mid 2015. During enrollment in this study, patients were prohibited to undergo further subsequent facial rejuvenating procedures. If a patient still did, the patient was excluded from the study.



### Procedures

At operating day, but before intervention, measurements were performed by the blinded investigator (JCNW) to determine base line values. All measurements were performed by the same investigator (JCNW) throughout the whole study, for every patient, at every follow-up moment (1 week, 3 months and 1 year post-operative) (Fig. 1) Clear patient instruction was given not to use any skin products on day of the operation nor during the different follow-up moments.

**Inclusion criteria:**

- Female, age 35-65 years
- Stable normal BMI (20-25, 1-year stable)

**Exclusion criteria:**

- Smoking
- Pregnancy or active child wish
- Prior operations in the mid-face
- Active or previous use of hormone replacement therapy.
- A known systemic disease that will impair wound healing (e.g. diabetes mellitus, known atherosclerosis with an event that required hospitalization, collagen diseases, diseases of the skin)
- A known psychiatric condition
- History of cancer

Pre-trial randomization

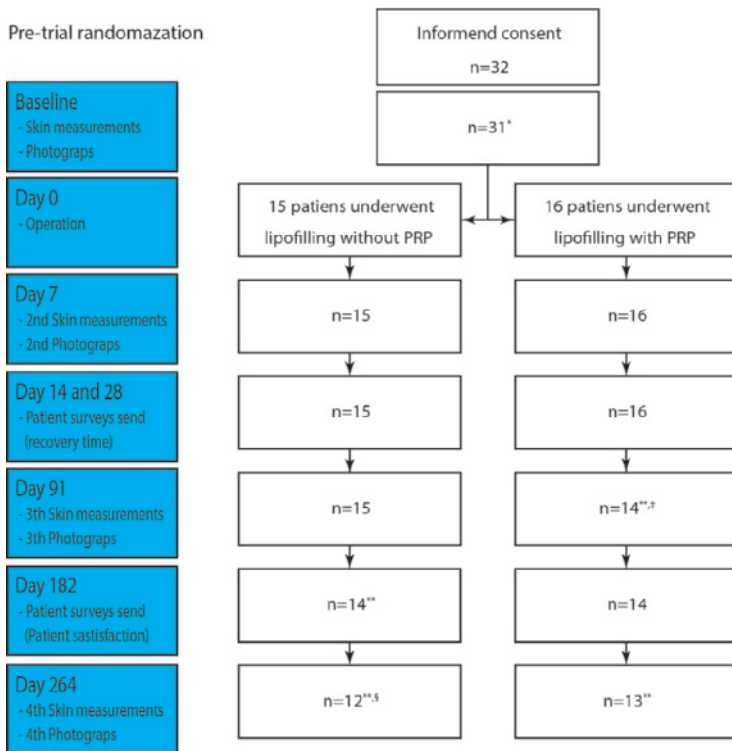
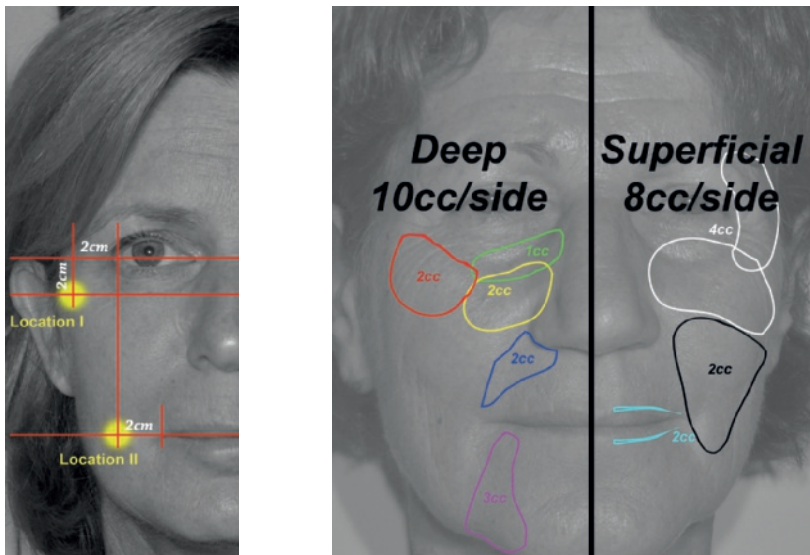


Figure 1. Study design with a breakdown of enrolled subjects that completed the study, and inclusion/exclusion criteria.

Excluded: \*patient was diagnosed with a gastro-intestinal oncological disease; \*\*patients failed to complete all follow-up moments by not showing up; †patient chose to leave the study due to personal circumstances; ‡patient underwent aesthetic facial surgery during the follow-up.

At the operating theater, with the patient mildly sedated, 30cc of whole blood was drawn from the patient, with an additional 2cc for platelet analysis. Following the pre-trial randomization, opening of the envelope determined whether the whole blood was either discarded, or introduced into the Biomet GPSIII device for PRP isolation (3cc PRP output) following the manufactures protocol. 3cc of sterile saline was used as placebo control.

Lipoharvesting, processing and lipofilling were performed following the standard Coleman method: however, both the lipoharvesting - and lipofilling cannulas were significant smaller (harvester: 2.4mm x 22cm, injector: 0.9mm x 5cm). The upper legs served as donor site in all patients. Location and applied lipofilling volume is presented in Fig 3. All procedures have been performed by the same surgeon (HPS), who at that time had already experience with more then 2000 lipofilling procedures. A detailed, step-by-step description of the lipofilling procedure is available online as video supplement<sup>5</sup>.



**Figure 2 (left).** Locations of skin measurements, shown locations were marked before each measurement. Patients lay down on an examination table to enable correct Cutometer probe placement. Location I: 2cm lateral and 2 cm caudal from the lateral canthus. Locations II: 2 cm lateral from the lateral commissure.

**Figure 3 (right).** Lipofilling locations and applied volume. Both superficial and deep lipofilling was performed on both sides of the face. In total 18cc per side, 36cc in total. Within the PRP group, 3cc of PRP was added into the lipofilling planes.

Legend:

Deep: Temporal projection (red), Nasojugal groove (green), Central midface (yellow), Nasolabial-fold (blue), Marionette-line, Pre-jowling area and chin (pink).

Superficial: Temporal and central midface area (white), Lower midface-cheek area (black), White rolls (cyan)

### Skin measurements

Local skin quality was measured with the Multi Probe Adapter system (C&K Colone Germany) containing the Cutometer MPA580 (elasticity) probe. The cutometer is a valid method in objectifying elasticity of the skin<sup>12-16</sup>. Measurements were done on fixed locations for every patient (Fig. 2) at every follow-up moment. Before each measurement, the probes were calibrated and tested for correct function. Also local temperature and humidity were logged. True skin elasticity was defined by the Cutometer MPA850 R7 output parameter (the ratio of elastic recovery to the total deformation, elaborated by the R5 (the net elasticity) and R6 (the ratio of viscoelastic to elastic extension) parameters.

#### *Volumetric changes of the nasolabial fold*

Standardized photographs were captured in three views with a professional 3D camera system (AP, 3Q left and right) at every follow-up moment. Primarily, 3D reconstructions were used to determine volumetric facial changes over time, but were abandoned due to data inconsistency, variation and reproducibility of the measured area. Instead, the pre-operative, 3 months and 1 year post-operative AP-views were used to determine changes in the nasolabial fold depth using a validated grading method (Merz Scale)<sup>17-20</sup>, that consists of five options (I=minimal fold expression to V=most prominent fold expression) In total, four independent plastic surgeons served as expert panel. The nasolabial fold was chosen because alteration in depth would implicate relevant external changes of facial appearance.

#### *Patient reported recovery time and satisfaction*

Recovery after the procedure was assessed by means of two patient questionnaires send at 2 and 4 weeks after the operation. Questions included the number of days required to return to work and or resume social activities without using camouflaging agents, and notable changes in facial volume and skin expressed on a visual analogue scale (VAS 1: no changes -10: most significant changes).

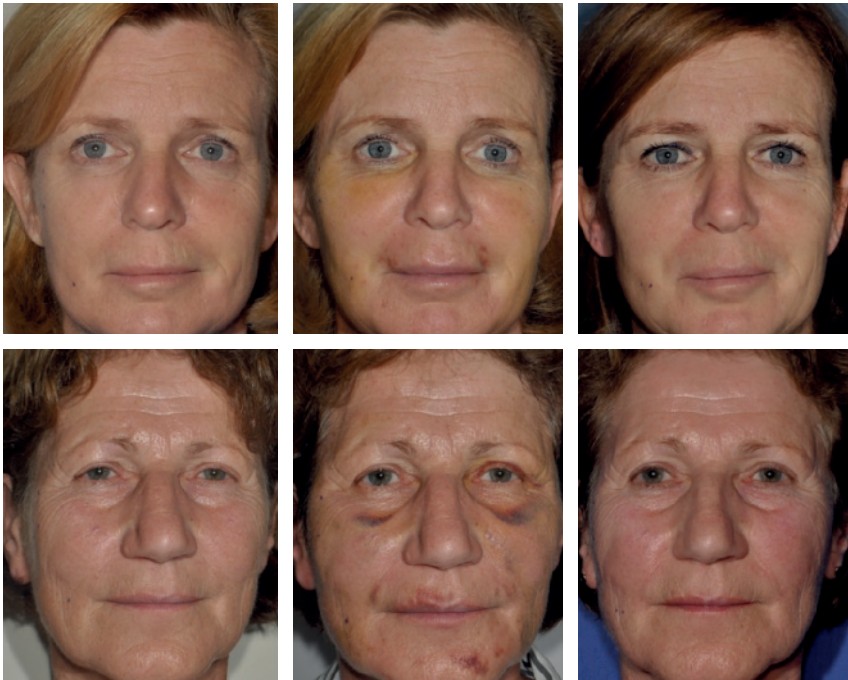

Figure 4. Average results: pre-operative (left column), 1 week (center column) and 1 year (right column) AP photographs. Upper row: PRP +, second row: PRP -.

Patient reported satisfaction was recorded by means of a questionnaire send 6 months after surgery: questions included overall satisfaction, changes in volume effect, skin changes and whether or not they would recommend the procedure to a peer (VAS 1-10).

*Statistical analysis*

Statistical analyses were performed by an independent statistician that received all blinded data by the principal investigator, along with the original randomization from the surgeon. All analyses were done using SPSS 20 (IBM, Chicago, IL, USA). Data Fig.s were generated using Prism 6 (GraphPad Software, La Jolla, CA, USA). The paired samples t-test, ANOVA analysis of covariance and standard linear regression were used. All data fulfilled the requirements for normality and equal variances. A two-sided  $p < 0.05$  was considered statistically significant.

**Results**

In total 32 patients, that met inclusion criteria, were enrolled in this study, with finally 25 patients completing the study. Seven patients were excluded from the study: four patients failed to complete all follow-up moments by not showing up, one patient was diagnosed with a gastro-intestinal oncological disease (ruled as undiagnosed pre-existent, and unconnected with the study ruled by the independent physician), one patient underwent aesthetic facial surgery during the follow-up, and one patient chose to leave the study due to personal circumstances. Excluded patients, unfortunately, could not be replaced due to limited study duration as allowed by the Ethical board.

Of all patients that completed the study, 13 received lipofilling with PRP (PRP+) and 12 lipofilling with saline (placebo, PRP-). Average photographic results are presented in Fig 4. Mean patient age at time of operation was 52 years ( $\pm 6.75$ , [38-63]), with no significant age difference between both groups. Whole blood platelet counts were within normal range for all patients (Table 1).

Table 1. Study population characteristics

	Group I No PRP(n=12)			Group II PRP(n=13)			<i>p</i> *	Overall (n=25)		
	Mean	(SD)	[Range]	Mean	(SD)	[Range]		Mean	(SD)	[Range]
-Age at time of operation	52.5	(7.1)	[42-63]	51.73	(6.7)	[38-62]	ns	52.10	(6.8)	[38-63]
-Platelet count	234.2	(47.9)	[153-299]	250.1	(37.5)	[168-312]	ns	242.8	(42.9)	[153-312]
	n			n			<i>p</i> *	n		
-Recorded complications (major and minor)	0			0			--	0		

\* students' t-test

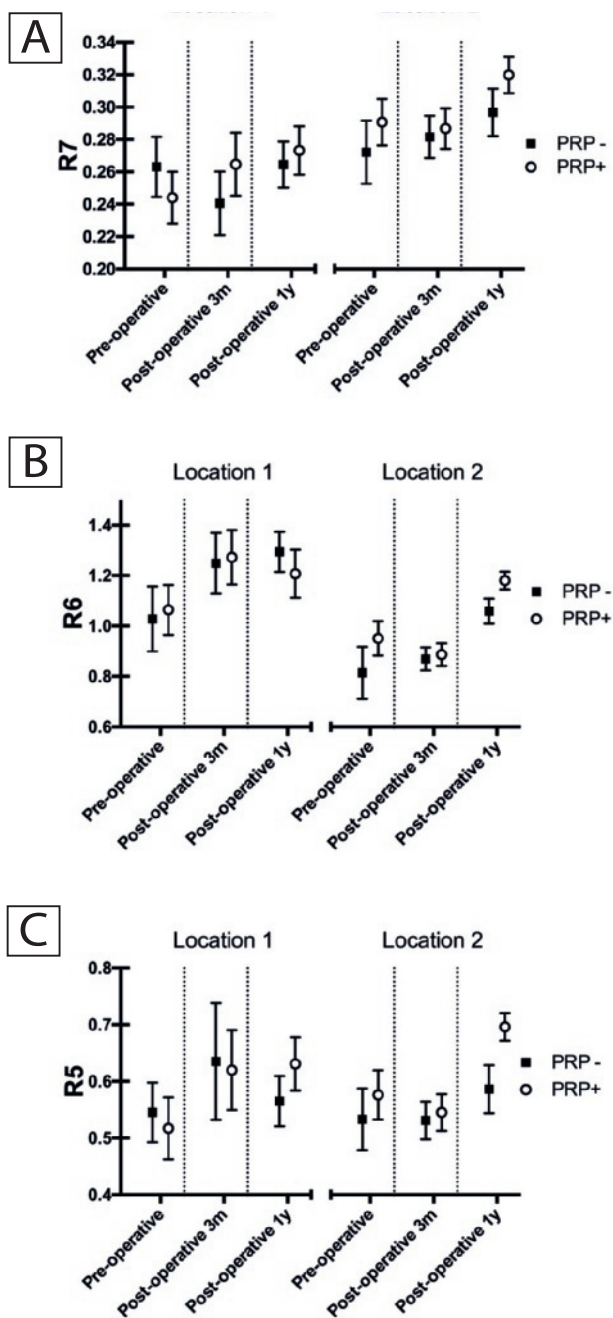


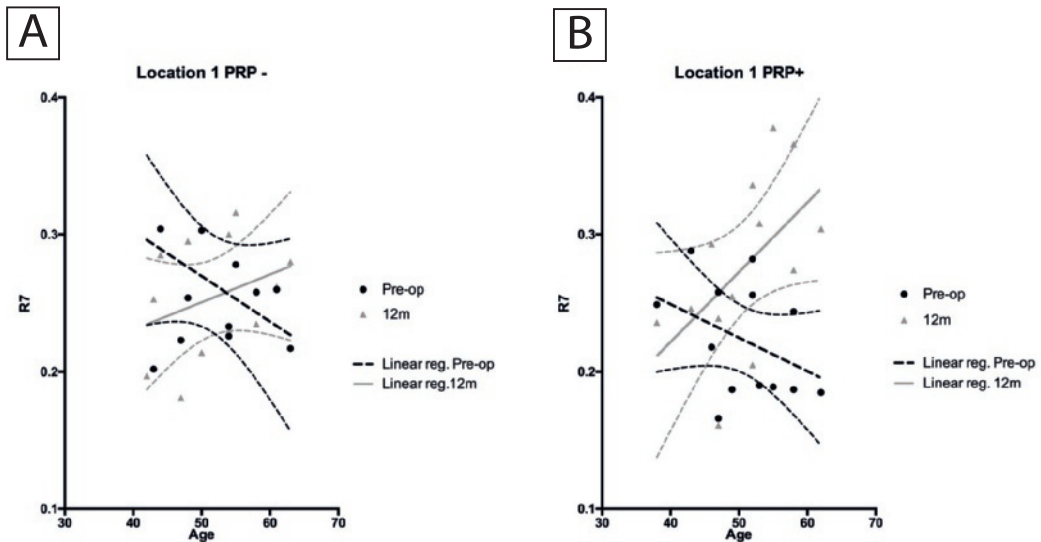
Figure 5. Changes in average true skin elasticity (R7) and R5-6 parameter, for both groups preoperative and during follow-up measured with Cutometer MPA850 at both locations. Data represents group means with SEM. A: R7 parameter location 1 and 2: true skin elasticity, higher values represent an increase in skin elasticity and a positive effect. There is a marginal increase in both groups, with no significance. B: R6 parameter location 1 and 2: the ratio of viscoelastic to elastic extension. Lower values represent a positive effect. Again, a minimal gain in both groups, with no significant differences, between both groups or within each group at every follow-up moment.

*Lipofilling with or without PRP does not significantly change overlying skin elasticity in this study.*

Analyzed R7 parameter data (representing true elasticity) from both groups, showed no significant difference before intervention (Fig. 5). The PRP+ group did not differ significantly from the placebo group at any moment. Data correction for age, room temperature, humidity conditions and baseline (pre-operative) measurements resulted in similar findings.

Analyzed R5 and R6 data showed comparable values in both groups, at every follow-up moment.

Regression analysis of pre-operative R7 parameter as a function of age showed a negative correlation in both groups, comparable to Enzure et al.<sup>21</sup>. However, after intervention, the correlation reverses (Fig. 6), which could be a sign of facial rejuvenation. Changes were most noticeable in the PRP+ group: the high prediction value of the regression line ( $R=0.542$ ,  $p=0.055$ ) could suggest that sample size in this study was not adequate. Interestingly this reversal was only notable on Location 1 R7, not on location 2 nor with the R5-R6 parameters.

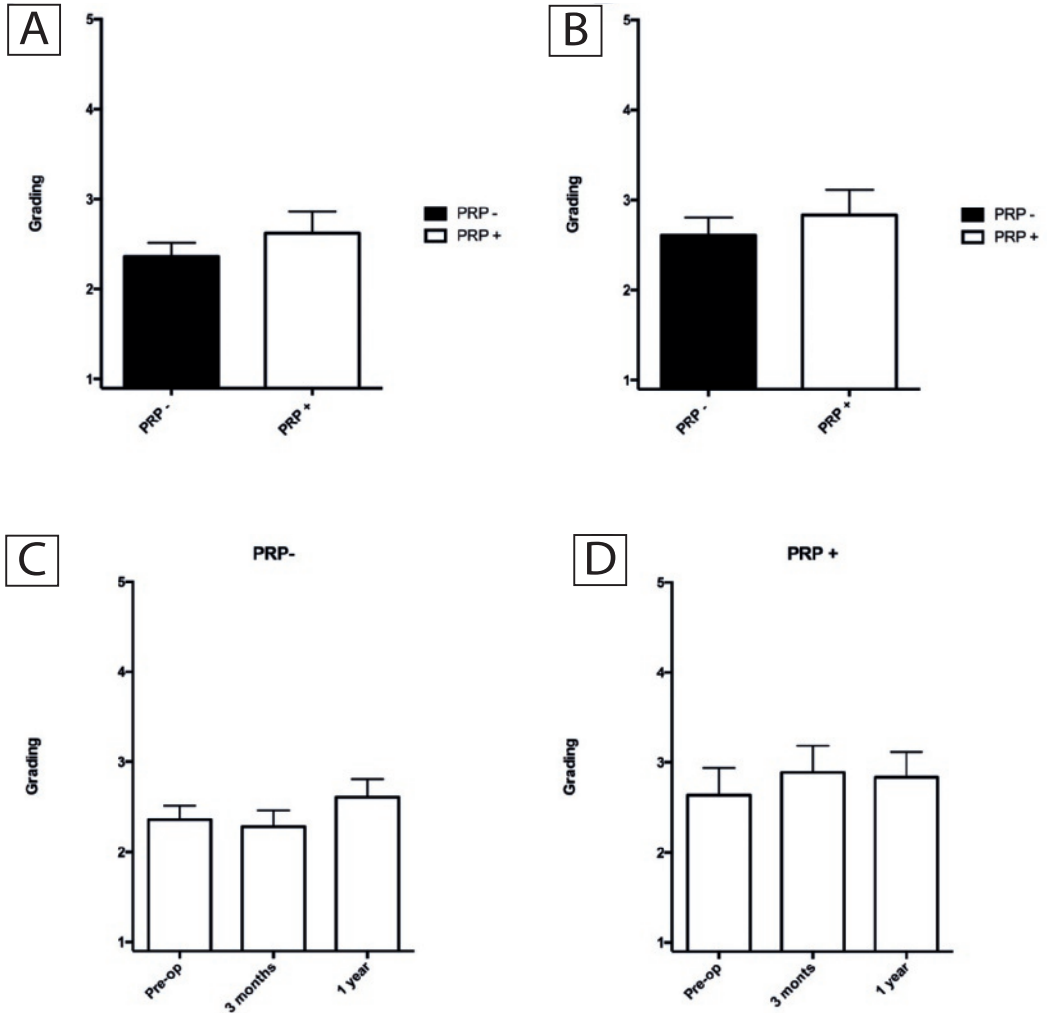


**Figure 6.** Regression analysis of true skin elasticity as a function of age, before and 12 months after intervention. All measurements and the calculated regression curve with 95% C.I. are presented A: PRP-. Pre-operatively age correlates negatively with true elasticity ( $y = -0.003293x + 0.4343$   $R = 0.402$   $p = 0.195$ ), but this correlation reverses 12 months post-operatively ( $y = 0.002005x + 0.1507$   $R = 0.326$   $p = 0.299$ ). B: PRP+. Again, a negative correlation before operation ( $y = -0.002444x + 0.3471$   $R = 0.392$   $p = 0.184$ ), with a stronger reversal after intervention ( $y = 0.005078x + 0.01921$   $R = 0.542$   $p = 0.055$ ) compared to PRP-.

*Changes of the nasolabial fold*

Summarized data from both groups, at every follow-up moment are presented in Fig. 7, lower scores represent a less prominent nasolabial fold. Grading scores showed a high level of agreement between each expert (all Spearman ICC  $r > 0.576$ ,  $p < 0.001$ ).

Pre-operative scores were comparable in both groups (PRP-:  $\mu: 2.359 \pm 0.1531$ , PRP+:  $\mu: 2.622 \pm 0.2388$ ,  $p > 0.05$ ). Data after 3 months and 1 year also showed comparable results, with no significant differences between both groups at any moment. Furthermore, no changes between pre- and postoperative scores within each group were found.



**Figure 7.** Result of nasolabial fold grading preoperative and during follow-up. Data represents group means with SEM from grading's by four experts. Lower scores represent a less prominent nasolabial fold. No significant differences, between both groups or within each group at every follow-up moment could be calculated. A: Pre-operative scores for both groups B: Post-operative scores for both groups C-D: Changes in grading's during follow-up for both groups. No effect was observed during follow-up.

Tabel 2. Recovery time\*

Facial Lipofilling	Group I PRP- (n=12)	Group II PRP+ (n=13)	p**
	Mean (SD)	Mean (SD)	
-RTW/social activities with camouflaging agents	15.4 (9.1)	9.1 (3.7)	0.010
-RTW/social activities without camouflaging agents	20.6 (6.6)	14.9 (4.6)	0.011

\*Recovery time was defined as the patient reported number of days after surgery returning to work (RTW)/social activities

\*\*Independent sampels t-test

*Addition of PRP speeds up recovery, but does not increase patient satisfaction.*

Patient questionnaire reported recovery time, derived from the number of days returning to work/social activities with or without camouflaging agents, showed a significant faster recovery in the PRP+ group (Table 2). Mean number of days returning to work/Social activities with camouflaging agents was 9 days ( $\mu=9,133 \sigma=3,701, p<0.01$ ) in the PRP+ group and 15 days in the control group ( $\mu=15,43 \sigma=4,949$ ). Return to work/social actives without camouflaging agents supported this finding (PRP +:  $\mu=14,87 \sigma=4,604$  vs PRP -:  $\mu=20.57 \sigma=6.61 p<0.05$ ). Questions regarding noticeable differences in facial volume and skin quality after 2 and 4 weeks showed no differences. ( $p > 0.05$ )

Patient satisfaction, changes in volume and skin quality, reported after 6 months proved to be similar in both groups (data not presented). Overall satisfaction was reported as ‘moderate’. Positive skin changes were reported by several patients in both groups, contradicted by patients that did not notice any skin changes at all. Overall, the level of recommendation of the procedure to peers was negative for both groups, mainly as told by them because of higher expectations of the effect of the procedure.

## Discussion

This randomized placebo controlled double blinded study was undertaken to investigate the possible beneficiary effects of adding PRP to aesthetic facial lipofilling in a well-defined healthy patient cohort. The results clearly demonstrate that the addition of PRP to the lipograft significantly reduces patient’s reported recovery time. However, the addition of PRP to the lipograft does not significantly improve skin elasticity, changing in nasolabial fold depth nor overall patient satisfaction as compared to lipofilling alone. The reversal in the correlation of net elasticity as a function of patient age could suggests some form of rejuvenation by lipofilling that is enhanced by PRP, but lacked significance with the number of patients in this study.

Reported in vitro effects of PRP <sup>10, 22-24</sup> thus could not be reproduced in our clinical study setting, possibly by incontrollable patient related confounding factors combined with a small therapeutic window for effect. Moreover, reported effects of ‘normal’ (not SVF/ASC enriched) lipofilling on skin rejuvenation, as has been reported and suggested to be seen in clinical studies when used in combination with facelift surgery<sup>2, 9</sup> could also not be addressed and forces us to question what the additional effect (next to some volume enhancement) of normal lipofilling is when used during facelift surgery.



*Lipofilling does not increase skin elasticity in the aging face, even with added PRP.*

Since the comeback of lipofilling, suggestions were made that it is 'more than a filler'<sup>2</sup> and may induce rejuvenation of the skin. However, this ASC induced effect, is only well studied after deep dermal injury (e.g. thermal- radiation damage, excessive scarring<sup>4, 25-27</sup>). Surprisingly skin rejuvenation of the normal aging skin has only been described, and studied histologically by Rigotti et al.<sup>9</sup> In this study, an increase in dermal elastin deposition was reported in biopsies after normal lipofilling of the aging skin. However, to this date, no controlled studies were done to verify the clinical relevancy of their finding. In our study, skin elasticity was determined with the Cutometer since it is a reliable and validated method of measuring skin age, and the mostly likely candidate to show changes, supported by the findings of Rigotti et al. Nevertheless, there remains minor controversy regarding the reliability of the Cutometer. A study of Nedelec et al. presented low intraclass correlation coefficients of skin elasticity measurements of dermal scars. The intraclass correlation coefficients found for normal skin elasticity measurements were, however, acceptable for the R0 (0.81), R6 (0.81) and R7 (0.78) parameter<sup>28</sup>. We found that normal (not SVF/ASC boosted) lipofilling with or without PRP did not alter skin elasticity. Reversal of the correlation between age and elasticity however, might suggest a small effect size, thus not significant with our small study population. Nevertheless, the small effect size raises questions if normal lipofilling is 'just a filler' in aesthetic procedures in the aging face which involve only lipofilling. Improvement in outcome when lipofilling is combined with lifting procedures could be explained by the large wound surface created and ASC modulation during healing, downregulating fibrosis pathways. Recent publication on SVF boosted/ASC expanded lipofilling however, do show a significant clinical effect<sup>29, 30</sup> and seem the way forward.

In theory, adding PRP could affect overlying skin true several pathways and cell lines. Angiopoietin-1 and 2, abundantly present in platelets<sup>31, 32</sup> have shown to stimulate endothelial cell growth, migration and differentiation in cultured human dermal microvascular endothelial cells in vitro<sup>22, 23</sup>. Also, PRP-lysate is a strong proliferator for ASC<sup>10, 33</sup>, essential for graft take<sup>34</sup> and a proven down regulator of fibrosis<sup>26, 35</sup>.

*Effects of lipofilling with or without PRP on nasolabial fold depth.*

Grading of the nasolabial fold during follow-up showed no noticeable lasting effect of lipofilling nor lipofilling with PRP on the depth of the nasolabial fold. Even though the "Merz Scale" used in this study, has shown to successfully differentiate in small volume changes ( e.g. filler injection)<sup>36</sup> We could not determine these differences probably because the lipofilling increased overall facial volume, not altering relative differences between facial zones. In our opinion, only in combination with a facelift, lipofilling may additionally demonstrate its effect on the nasolabial fold: lifting probably is definitely needed as such. Furthermore, changes in facial volume are minimal because of the limited amount of lipografts that is injected, with uncertainty about the clinical impact of these minor changes if not combined with a lifting procedure. To this date, only one study has been published that reported facial graft retention determined with external 3D photographic reconstruction<sup>37</sup> after aesthetic facial lipofilling. In this study, an overall retention of 32% was reported, however the range and variation of reported data questions its scientific merit. Moreover, the vast number of patients in this study also received some form of lifting procedure that most likely changed distribution of facial volume, and by this means influenced facial volume attributed to lipofilling. Again suggesting that lipofilling should be combined with a lifting procedure in aesthetic facial rejuvenation. Even though lipograft survival in the face has been documented with MRI imaging<sup>38</sup>, the clinical relevancy of aesthetic facial lipofilling procedures without lifting procedures on facial fold depth remains to be determined.

With ongoing uncertainty about lipograft survival, several fundamental studies explored PRP addition<sup>39-41</sup> and found positive effects. Graft take might improve by PRP effects on ASC proliferation<sup>39</sup>, blockage of apoptosis pathways<sup>42</sup> and differentiation into adipocytes<sup>43</sup>. Moreover, PRP lysate stimulates proliferation, migration and tube formation of human umbilical vein endothelial cells both in vitro as well as in a nude mouse model<sup>39</sup>. PRP induces changes on endothelial cells that can contribute to (neo)angiogenesis of the fat graft and thereby enhance fat graft survival<sup>44</sup>. These findings however, fail to make a significant impact in the majority of available clinical PRP-lipofilling studies<sup>45,46</sup>, thus questioning clinical use of PRP addition to lipofilling for this reason.

#### *PRP speeds up patient recovery*

Patient reported recovery time was significantly reduced by the addition of PRP in this study. This finding is in line with previous data from our retrospective study<sup>11</sup> and current literature on aesthetic procedures like fractional carbon dioxide laser resurfacing treatment<sup>47,48</sup>.

Dermal- and wound closure effects observed after PRP injection might be explained by the effect from PRP on fibroblasts. In vitro study of Ramos-Torrecillas et al.<sup>49</sup> eases the growth of fibroblasts and induces their differentiation into myofibroblasts, thus playing a key part in wound contracture<sup>22</sup>. Collagen 1 and extracellular matrix remodeling by fibroblast is also affected by PRP. Fibroblast exposed to PRP lysate in vitro up regulates the expression of Matrix metalloproteinase (MMP)-1<sup>24</sup>, which in its turn plays a key role in collagen remodeling. Also, type 1 collagen expression is increased under these circumstances<sup>50</sup>. Increased fibroblast activity, along with changes in collagen production and a potentially stronger inflammation response<sup>51</sup> could also play a role in our observed reduced recovery time after surgery when the lipograft was combined with PRP.

#### *The concentration paradox: Less is more?*

A potential pitfall in evaluating the effect of PRP is the lack of uniform concentrations of created PRP. The studies of Yamaguchi et al.<sup>52,53</sup> were the first publications that showed that a higher concentration of PRP (or more platelets) may produce counterproductive effects, possibly by unwanted cell differentiation. Most commercially available PRP kits capture a percentage of available platelets from whole blood, not a certain quantitative number of platelets. Considering the fact that normal human platelet counts are defined within a wide range and show large daily variations, the cumulative amount of growth factors in kit-isolated PRP is inconsistent<sup>54</sup>. This variation can inadvertently influence its effect in a way as is observed in vitro on different cell types<sup>22</sup>. Regarding cells present in the lipograft, PRP concentration alters ASC proliferation, function and behavior. High PRP concentrations increase proliferation, but also changes ASC into a fibroblast like phenotype, with increased collagen RNA expression and altered paracrine signaling that negatively influences endothelial vessel formation<sup>55,56</sup>.

Although platelet counts were normal within our well-defined healthy patient cohort, combined with comparable fat-graft-PRP-or-placebo mixture ratios, our study is potentially biased and weakened by this concentration-dependent effect. Moreover, this phenomenon could explain the failure of clinical studies.

Local growth factor conditions after lipofilling are also an issue that remains unclear; in a healthy patient, the release of platelets and pro-inflammatory factors due to damage caused by the lipofilling procedure itself could be of such an extent that the addition of PRP actually is insignificant and/or redundant or even too high.

## Conclusion

This randomized double-blinded, placebo-controlled study clearly has shown that PRP significantly reduces post-operative recovery time but does not improve patient outcome when looking at skin elasticity, improvement of the nasolabial fold nor patient satisfaction. The reversal of the correlation between age and elasticity might indicate for some effect on skin, but requires more power of future studies.

Thus far, the use of PRP as an additive in lipofilling has shown great promises in vitro. These beneficiary effects, however, have only partially been reproduced in a clinical setting. A growing number of studies report a concentration depended effect of PRP in vitro, making optimal use in a clinical setting delicate and complex. Further studies of PRP interactions on both the lipograft as well as the receptor host site involved cells seems to be of paramount importance to determine the optimal use and concentrations of PRP in a clinical setting.

## References

1. Zuk PA, Zhu M, Ashjian P et al. Human adipose tissue is a source of multipotent stem cells. *Molecular biology of the cell*. 2002;13:4279-95.
2. Coleman SR. Structural fat grafting: More than a permanent filler. *Plastic and reconstructive surgery*. 2006;118:108S-120S.
3. Nguyen A, Guo J, Banyard DA et al. Stromal vascular fraction: A regenerative reality? part 1: Current concepts and review of the literature. *J Plast Reconstr Aesthet Surg*. 2016;69:170-179.
4. Rigotti G, Marchi A, Galie M et al. Clinical treatment of radiotherapy tissue damage by lipoaspirate transplant: A healing process mediated by adipose-derived adult stem cells. *Plastic and reconstructive surgery*. 2007;119:1409-22; discussion 1423-4.
5. Willemsen JC, Mulder KM, Stevens HP. Lipofilling with minimal access cranial suspension lifting for enhanced rejuvenation. *Aesthetic surgery journal / the American Society for Aesthetic Plastic surgery*. 2011;31:759-69.
6. Pallua N, Wolter T. The lipo-facelift: Merging the face-lift and liposculpture: Eight years experience and a preliminary observational study. *Aesthetic Plast Surg*. 2013;37:1107-1113.
7. Cotofana S, Fratila AA, Schenck TL, Redka-Swoboda W, Zilinsky I, Pavicic T. The anatomy of the aging face: A review. *Facial Plast Surg*. 2016;32:253-260.
8. Ramirez OM. Full face rejuvenation in three dimensions: A "face-lifting" for the new millennium. *Aesthetic Plast Surg*. 2001;25:152-164.
9. Charles-de-Sa L, Gontijo-de-Amorim NF, Maeda Takiya C et al. Antiaging treatment of the facial skin by fat graft and adipose-derived stem cells. *Plast Reconstr Surg*. 2015;135:999-1009.
10. Liao HT, Marra KG, Rubin JP. Application of platelet-rich plasma and platelet-rich fibrin in fat grafting: Basic science and literature review. *Tissue Eng Part B Rev*. 2014;20:267-276.
11. Willemsen JC, van der Lei B, Vermeulen KM, Stevens HP. The effects of platelet-rich plasma on recovery time and aesthetic outcome in facial rejuvenation: Preliminary retrospective observations. *Aesthetic Plast Surg*. 2014;38:1057-1063.
12. Nedelec B, Forget NJ, Hurtubise T et al. Skin characteristics: Normative data for elasticity, erythema, melanin, and thickness at 16 different anatomical locations. *Skin Res Technol*. 2016;22:263-275.
13. Coltman CE, Steele JR, McGhee DE. Effect of aging on breast skin thickness and elasticity: Implications for breast support. *Skin Res Technol*. 2016.
14. Jaspers ME, Brouwer KM, van Trier AJ, Groot ML, Middelkoop E, van Zuijlen PP. Effectiveness of autologous fat grafting in adherent scars: Results obtained by a comprehensive scar evaluation protocol. *Plast Reconstr Surg*. 2016.
15. Ono I. A study on the alterations in skin viscoelasticity before and after an intradermal administration of growth factor. *Journal of cutaneous and aesthetic surgery*. 2011;4:98-104.
16. Draaijers LJ, Botman YA, Tempelman FR, Kreis RW, Middelkoop E, van Zuijlen PP. Skin elasticity meter or subjective evaluation in scars: A reliability assessment. *Burns*. 2004;30:109-14.
17. van Dongen JA, Eyck BM, van der Lei B, Stevens HP. The rainbow scale: A simple, validated online method to score the outcome of aesthetic treatments. *Aesthet Surg J*. 2016;36:NP128-30.
18. Shoshani D, Markovitz E, Monstrey SJ, Narins DJ. The modified fitzpatrick wrinkle scale: A clinical validated measurement tool for nasolabial wrinkle severity assessment. *Dermatol Surg*. 2008;34 Suppl 1:S85-91; discussion S91.
19. Buchner L, Vamvakias G, Rom D. Validation of a photonumeric wrinkle assessment scale for assessing nasolabial fold wrinkles. *Plast Reconstr Surg*. 2010;126:596-601.
20. Narins RS, Carruthers J, Flynn TC et al. Validated assessment scales for the lower face. *Dermatol Surg*. 2012;38:333-342.
21. Ezure T, Amano S. Influence of subcutaneous adipose tissue mass on dermal elasticity and sagging severity in lower cheek. *Skin Res Technol*. 2010;16:332-338.
22. Kushida S, Kakudo N, Suzuki K, Kusumoto K. Effects of platelet-rich plasma on proliferation and myofibroblastic differentiation in human dermal fibroblasts. *Ann Plast Surg*. 2013;71:219-224.
23. Kakudo N, Kushida S, Minakata T, Suzuki K, Kusumoto K. Platelet-rich plasma promotes epithelialization and angiogenesis in a splitthickness skin graft donor site. *Med Mol Morphol*. 2011;44:233-236.
24. Shin MK, Lee JW, Kim YI, Kim YO, Seok H, Kim NI. The effects of platelet-rich clot releasate on the

- expression of MMP-1 and type I collagen in human adult dermal fibroblasts: PRP is a stronger MMP-1 stimulator. *Mol Biol Rep.* 2014;41:3-8.
25. Sultan SM, Stern CS, Allen RJ, Jr et al. Human fat grafting alleviates radiation skin damage in a murine model. *Plast Reconstr Surg.* 2011;128:363-372.
  26. Conde-Green A, Marano AA, Lee ES et al. Fat grafting and adipose-derived regenerative cells in burn wound healing and scarring: A systematic review of the literature. *Plast Reconstr Surg.* 2016;137:302-312.
  27. Sultan SM, Barr JS, Butala P et al. Fat grafting accelerates revascularisation and decreases fibrosis following thermal injury. *Journal of plastic, reconstructive & aesthetic surgery : JPRAS.* 2012;65:219-27.
  28. Nedelec B, Correa JA, Rachelska G, Armour A, LaSalle L. Quantitative measurement of hypertrophic scar: Interrater reliability and concurrent validity. *J Burn Care Res.* 2008;29:501-11.
  29. Amirkhani MA, Shoaie-Hassani A, Soleimani M, Hejazi S, Ghalichi L, Nilfroushzadeh MA. Rejuvenation of facial skin and improvement in the dermal architecture by transplantation of autologous stromal vascular fraction: A clinical study. *Bioimpacts.* 2016;6:149-154.
  30. Rigotti G, Charles-de-Sa L, Gontijo-de-Amorim NF et al. Expanded stem cells, stromal-vascular fraction, and platelet-rich plasma enriched fat: Comparing results of different facial rejuvenation approaches in a clinical trial. *Aesthet Surg J.* 2016;36:261-270.
  31. Mammoto T, Jiang A, Jiang E, Mammoto A. Platelet rich plasma extract promotes angiogenesis through the angiopoietin1-Tie2 pathway. *Microvasc Res.* 2013;89:15-24.
  32. Mammoto T, Jiang A, Jiang E, Mammoto A. Platelet-rich-plasma extract prevents pulmonary edema through angiopoietin-Tie2 signaling. *Am J Respir Cell Mol Biol.* 2014.
  33. Blande IS, Bassaneze V, Lavini-Ramos C et al. Adipose tissue mesenchymal stem cell expansion in animal serum-free medium supplemented with autologous human platelet lysate. *Transfusion.* 2009;49:2680-2685.
  34. Kolle SF, Fischer-Nielsen A, Mathiasen AB et al. Enrichment of autologous fat grafts with ex-vivo expanded adipose tissue-derived stem cells for graft survival: A randomised placebo-controlled trial. *Lancet.* 2013;382:1113-1120.
  35. Spiekman M, Przybyl E, Plantinga JA, Gibbs S, van der Lei B, Harmsen MC. Adipose tissue-derived stromal cells inhibit TGF-beta1-induced differentiation of human dermal fibroblasts and keloid scar-derived fibroblasts in a paracrine fashion. *Plast Reconstr Surg.* 2014;134:699-712.
  36. Cohen SR, Berner CF, Busso M et al. ArteFill: A long-lasting injectable wrinkle filler material--summary of the U.S. food and drug administration trials and a progress report on 4- to 5-year outcomes. *Plast Reconstr Surg.* 2006;118:64S-76S.
  37. Meier JD, Glasgold RA, Glasgold MJ. Autologous fat grafting: Long-term evidence of its efficacy in midfacial rejuvenation. *Arch Facial Plast Surg.* 2009;11:24-8.
  38. Swanson E. Malar augmentation assessed by magnetic resonance imaging in patients after face lift and fat injection. *Plastic and reconstructive surgery.* 2011;127:2057-65.
  39. Kakudo N, Morimoto N, Kushida S, Ogawa T, Kusumoto K. Erratum to: Platelet-rich plasma releasate promotes angiogenesis in vitro and in vivo. *Med Mol Morphol.* 2014.
  40. Oh DS, Cheon YW, Jeon YR, Lew DH. Activated platelet-rich plasma improves fat graft survival in nude mice: A pilot study. *Dermatologic surgery : official publication for American Society for Dermatologic Surgery [et al ].* 2011;37:619-25.
  41. Pires Fraga MF, Nishio RT, Ishikawa RS, Perin LF, Jr AH, Malheiros CA. Increased survival of free fat grafts with platelet-rich plasma in rabbits. *J Plast Reconstr Aesthet Surg.* 2010.
  42. Fukaya Y, Kuroda M, Aoyagi Y et al. Platelet-rich plasma inhibits the apoptosis of highly adipogenic homogeneous preadipocytes in an in vitro culture system. *Exp Mol Med.* 2012;44:330-339.
  43. Cervelli V, Scioli MG, Gentile P et al. Platelet-rich plasma greatly potentiates insulin-induced adipogenic differentiation of human adipose-derived stem cells through a serine/threonine kinase akt-dependent mechanism and promotes clinical fat graft maintenance. *Stem Cells Transl Med.* 2012;1:206-220.
  44. Cervelli V, Gentile P, Scioli MG et al. Application of platelet-rich plasma in plastic surgery: Clinical and in vitro evaluation. *Tissue engineering.* 2009;15:625-34.
  45. Salgarello M, Visconti G, Rusciani A. Breast fat grafting with platelet-rich plasma: A comparative clinical study and current state of the art. *Plast Reconstr Surg.* 2011;127:2176-2185.
  46. Gentile P, Orlandi A, Scioli MG et al. A comparative translational study: The combined use of

enhanced stromal vascular fraction and platelet-rich plasma improves fat grafting maintenance in breast reconstruction. *Stem Cells Transl Med.* 2012;1:341-351.

47. Lee JW, Kim BJ, Kim MN, Mun SK. The efficacy of autologous platelet rich plasma combined with ablative carbon dioxide fractional resurfacing for acne scars: A simultaneous split-face trial. *Dermatologic surgery : official publication for American Society for Dermatologic Surgery [et al].* 2011;37:931-8.

48. Na JI, Choi JW, Choi HR et al. Rapid healing and reduced erythema after ablative fractional carbon dioxide laser resurfacing combined with the application of autologous platelet-rich plasma. *Dermatologic surgery : official publication for American Society for Dermatologic Surgery [et al].* 2011;37:463-8.

49. Ramos-Torrecillas J, Luna-Bertos E, Manzano-Moreno FJ, Garcia-Martinez O, Ruiz C. Human fibroblast-like cultures in the presence of platelet-rich plasma as a single growth factor source: Clinical implications. *Adv Skin Wound Care.* 2014;27:114-120.

50. Cho JW, Kim SA, Lee KS. Platelet-rich plasma induces increased expression of G1 cell cycle regulators, type I collagen, and matrix metalloproteinase-1 in human skin fibroblasts. *Int J Mol Med.* 2012;29:32-36.

51. Dragoo JL, Braun HJ, Durham JL et al. Comparison of the acute inflammatory response of two commercial platelet-rich plasma systems in healthy rabbit tendons. *The American journal of sports medicine.* 2012.

52. Yamaguchi M, Matsumoto F, Bujo H et al. Revascularization determines volume retention and gene expression by fat grafts in mice. *Experimental biology and medicine (Maywood, N J.* 2005;230:742-8.

53. Yamaguchi R, Terashima H, Yoneyama S, Tadano S, Ohkohchi N. Effects of platelet-rich plasma on intestinal anastomotic healing in rats: PRP concentration is a key factor. *The Journal of surgical research.* 2010.

54. Mazzocca AD, McCarthy MB, Chowanec DM et al. Platelet-rich plasma differs according to preparation method and human variability. *The Journal of bone and joint surgery American volume.* 2012;94:308-16.


55. Graziani F, Ivanovski S, Cei S, Ducci F, Tonetti M, Gabriele M. The in vitro effect of different PRP concentrations on osteoblasts and fibroblasts. *Clinical oral implants research.* 2006;17:212-9.

56. Willemsen JC, Spiekman M, Stevens HP, van der Lei B, Harmsen MC. Platelet-rich plasma influences expansion and paracrine function of adipose-derived stromal cells in a dose-dependent fashion. *Plast Reconstr Surg.* 2016;137:554e-565e.





# THE CONCENTRATION DEPENDENT EFFECT OF PLATELET RICH PLASMA ON ADIPOSE STEM CELLS IN VITRO

- 
- A vertical white line with a solid white circle at each end is positioned to the left of the author list.
1. JOEP C.N. WILLEMSSEN
  2. MAROESJKA SPIEKMAN
  3. HIERONYMUS P.J.D. STEVENS
  4. BEREND VAN DER LEI
  5. MARTIN C. HARMSSEN



### *Introduction*

Lipofilling is an accepted treatment modality in the (re)construction of tissue volume. PRP has been suggested to increase graft take, yet the efficacy is met with skepticism. Similarly, ADSC are put forward as a candidate to augment graft take and tissue rejuvenation. We hypothesized that the variation reported in literature is caused by a dose-dependent influence of PRP on ADSC.

### *Results*

The presence of PRP in culture medium affected the expression of genes in a dose-dependent, gene-specific manner. PRP-15% stimulated proliferation almost eight times. Mesenchymal markers were unaffected. Interestingly, expression of genes for COL1,3 increased at lower concentrations, while TGFB, showed a reduced expression in lower concentrations. Pro-angiogenic gene expression was unaltered or strongly reduced in a dose-dependent manner. In vitro, PRP promoted endothelial sprouting and survival in a dose-dependent manner, however, conditioned medium from ADSC exposed to PRP, blocked endothelial sprouting capabilities.

### *Material and Methods*

Whole blood (n=3) was used to generate PRP which was diluted with DMEM to 15%,5% and 1.7%, with 15%-PPP and 10%-FCS as controls. Pooled ADSC (n=3) were cultured in these media. ADSC gene expression was assessed, along with angiogenic sprouting of endothelial cells by conditioned medium and PRP.

### *Conclusion*

ADSC respond to PRP in a dose-dependent way in vitro. PRP caused a dose-dependent increase of the proliferation. Moreover, ADSC showed a dose-dependent decrease of paracrine genes relevant to tissue repair or engraftment of lipografts. This was corroborated by the near abolished capacity of ADSC to support angiogenic sprouting of endothelial cells in vitro after treatment with high concentrations of PRP.

## Introduction

Fat-grafting, or lipofilling has become an accepted treatment modality in the (re)construction of tissue volume. Indications vary from acquired to hereditary loss<sup>2</sup> of volume in both aesthetic as well as reconstructive surgery.

Although technical improvements have increased the overall fat graft take dramatically<sup>3</sup>, the level of fat graft survival is still uncertain and suboptimal<sup>4</sup>. Various methods have been suggested to increase graft take, which include negative pressure garments<sup>5</sup>, addition of ADSC to grafts<sup>6</sup> and addition of platelet derived growth factors<sup>7</sup> or platelet rich plasma (PRP). The efficacy of these procedures however, still has to be proven in randomized clinical trials.

Besides the volumetric effect observed after a lipofilling procedure, skin rejuvenation features are observed like decreased pore size, improved elasticity and suppression of inflammatory skin conditions as well as reduction of existing scars<sup>1,8</sup>. The presence of ADSC in the lipograft is suggested to participate in tissue rejuvenation features as well as improved wound healing<sup>9</sup>. These ADSC achieve this either by direct support of the lipograft during the first days, facilitating vessel ingrowth, or by differentiation into adipocytes or both<sup>10</sup>.

PRP, as investigated by Marx et al<sup>11</sup>, is rich in growth factors that support wound healing in normal physiology. These growth factors, such as PDGF, TGF- $\beta$  and VEGF locally influence migration, proliferation and differentiation<sup>12</sup> of several cell-types including endothelial cells (angiogenesis) and (myo)fibroblasts (deposition of extracellular matrix). In animal studies, PRP augments graft take<sup>13-16</sup>, most likely due to improved vascularization. Moreover, addition of PRP to fat grafts, reduces the occurrence of oil cysts<sup>17</sup>. However, the clinical efficacy of the use of PRP is highly variable<sup>18-20</sup>, which causes doubt about the benefit of PRP to support and improve graft take<sup>21</sup>.

From a pharmacological point of view, it is to be expected that PRP would act in a dose-dependent fashion in combination with lipofilling. Therefore, the observed clinical variation in the effect of PRP could be due to concentration differences. In vitro, fibroblasts and osteoblasts react in a dose-related response to PRP<sup>22-26</sup>.

Studies that explore the influence of PRP on the proliferation and cellular function of ADSC are limited<sup>21</sup>. Besides PRP, ADSC appear a promising factor to influence graft take and tissue regeneration<sup>10,27,28</sup>, which underlies our in vitro study to investigate the influence of PRP concentration - on the proliferation, phenotype and function of ADSC.

## Methods

### *ADSC isolation and culture*

Human adipose tissue was collected from the resected abdominal skin flap from three healthy abdominoplasty patients (BMI < 30) after informed consent. This source of ADSC was approved by of the local Ethics Committee (anonymized waste material).

The skin flaps were processed using a working protocol for ADSC isolation<sup>29</sup>. Isolated ADSC were expanded to passage 3 in Dulbecco's modified Eagle's medium (DMEM, Lonza) supplemented with 10% fetal calve serum (FCS) (Thermo Scientific, Hempstead, UK), 1% L-glutamine (Lonza Biowhittaker Verviers, Belgium), and antibiotics at 37°C. For the experiments, ADSC of all three donors (P3 and higher) were pooled.

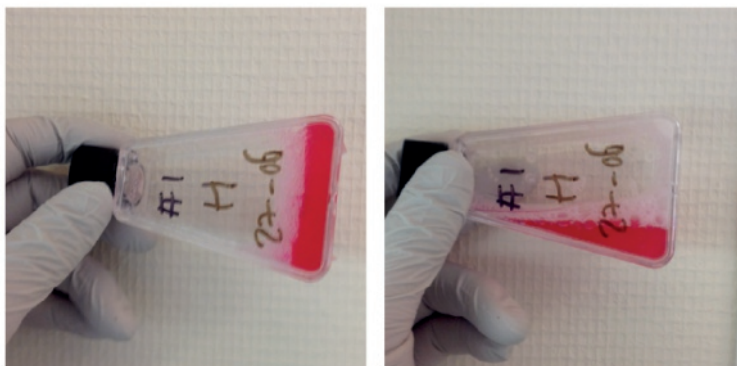
### *Preparation of PRP and PPP*

Whole blood was drawn (27 ml) from three healthy volunteers and mixed with 3 ml of citrate (standard ACD-A solution) to prevent clotting. Additional blood samples were used platelet, RBC and WBC counts. The whole blood citrate mixture was introduced into the Biomet GPS-III device (Biomet, Warsaw, Indiana) following the manufacturer's instructions. Fifteen minutes of centrifugation at 2,200x g separated the blood into three fractions: erythrocytes, platelet-poor plasma (PPP), and platelet-rich plasma (PRP). Output volume of the PRP was 3 ml, a ninefold reduction of the input volume. PPP and the PRP were collected separately with a syringe. To prevent inhibition of ADSC's proliferation, residual leukocytes and erythrocytes were removed too (300x g for 10min) <sup>30</sup>.

### *PRP dilution*

The PRP was diluted with DMEM to final concentrations of respectively 15%, 5% and 1.7%, while PPP was diluted to 15% only. Experiments with endothelial cells, were performed in endothelial cell culture medium (ECM -RPMI-1640, 5 µg/ml endothelial cell growth factors<sup>31</sup> (Bovine brain extract), 5 U/mL heparin (Leo Pharma, Holland), 2 mM L-glutamine). Diluted PRP was activated through vigorously shaking (clot formation, Fig. 1). The clot was resuspended by breaking and pipetting with a pipet tip, several times.

As control, 10% or 20%-FCS was used instead of PRP or PPP.



**Figure 1.** Activation, gelling and resuspension of PRP

The PRP was diluted with DMEM to final concentrations of respectively 15%, 5% and 1.7%, while PPP was diluted to 15% only. Left panel: PRP was activated separately after their diluting, through vigorously shaking the tubes, which resulted in the formation of a clot. Right panel: resuspension of the clot by pipetting up and down several times.

### *Proliferation*

Confluent cultures of pooled ADSC (P4) were seeded in 24 well plates at 4x10<sup>4</sup>/cm<sup>2</sup> (t=-1d). After 24h (d0) media were replaced by the PRP-PPP conditions that were generated on d0 too. After 4d, cells were fixed with 2% paraformaldehyde-PBS for 20min. Following extensive washing, cells were permeabilized with 0.5% Triton X-100-PBS (Sigma-Aldrich,MA). Subsequently, plates were incubated with polyclonal rabbit-anti-human Ki67 antibody (Monosan,Holland) diluted 1:250 in PBS-10% horse serum (First Link Ltd,UK) for 90min. Control

wells received only detection antibody. After washing, the wells were incubated with donkey-anti-rabbit serum conjugated to Alexa Fluor 488 (Life Technologies, Carlsbad,CA) diluted 1:300 in 0.5 µg/mL DAPI-PBS and 2% horse serum for 30min followed by a final washes with PBS. The wells were scanned using automated immunofluorescent microscopy using a Zeiss AxioObserver-Z1 microscope on 10x magnification (TissueGnostics,Vienna,Austria). Two wells were scanned per condition per PRP donor (n=3). TissueQuest cell analysis software (v4.0.1.0.127) determined the total cell-count and percentage of Ki67 expressing cells.

#### *Gene expression by qRT-PCR*

At t =-1d, confluent cultures of pooled ADSC (P4) were seeded in 6-well plates at 4x10<sup>4</sup>/cm<sup>2</sup>. After 24h (d0), media were replaced with medium with 1.7, 5 and 15% PRP respectively or medium with 15% PPP or 10% FCS.

After 4d, cells were lysed in using Trizol Reagent (Life technologies, Carlsbad,CA) and total RNA was isolated according to the manufacturer's protocol. Two µg of total RNA was reverse transcribed using a First-Strand cDNA synthesis kit (Thermo-Scientific, Waltham,MA). The cDNA equivalent of 10ng RNA was amplified (triplicates) using the SyberGreen method (Life Technologies) using specific primers (Table 1.) SHuman beta-actin was used as reference. PCRs were performed by a ViiA-7 real-time PCR system (Life Technologies), with Cycle threshold (CT) values for individual reactions obtained from the ViiA-7 software. Relative expression was calculated using the delta-CT method.

#### *Endothelial sprouting*

Conditioned medium (CM) from pooled ADSC (P4) was prepared from 4d cultures in ECM with PRP, PPP or FCS. This was followed by incubation in the absence of PRP, PPP or FCS for 16h. Inner wells of µ-Slide Angiogenesis plates (Ibidi GmbH,Germany) were coated with 10µL MatriGel™ (BD Biosciences,CA). Pooled P4 Human Umbilical Vein Endothelial cells (HUVEC,Lonza Biowhittaker) were suspended (200,000 cells/mL) in the prepared CM, ECM-PRP media and ECM-PPP medium using the same dilutions as described above. ECM FCS-20% and CM from ADSC cultured on ECM-FCS-10% served as positive control, serumfree ECM as negative. In total, 10,000 HUVEC were pipetted per well (triplicates). Light micrographs (2.5x magnification) were evaluated after 6, 16, 24 and 72h (72h ECM-PRP wells only). The number of sprouts, quantified in number of loops and branches and length, was calculated with the Angiogenesis-analyzer (Image J, NIH, Bethesda,Maryland, USA)<sup>32</sup>


#### *Statistics*

Data were analyzed by GraphPad Prism (v6.0,GraphPad Software Inc., LaJolla,CA), and presented as means with SEM (±). Statistical significance was determined using one-way ANOVA with Bonferroni's comparison post-hoc analysis. Differences with p<0.05 were considered significant.

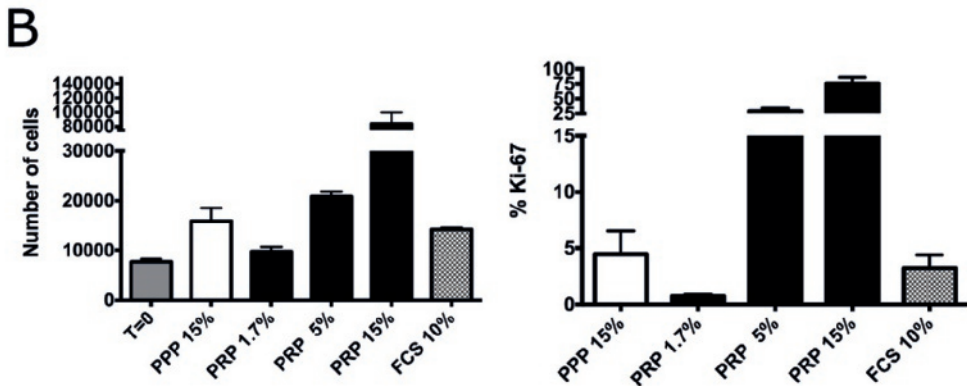
## **Results**

#### *PRP donors*

A total of 3 ml PRP was generated per donor; with donor platelet counts all within normal range (251 ± 39.13, range 180-315). Donors' RBC and WBC counts were normal.



**Figure 2.** PRP promotes cell proliferation in a dose-dependent fashion. A: i, ii – light micrographs (10 and 20-fold original magnification respectively) showing the PRP concentration-dependent increased proliferation of ADSC after 3d culture. iii - PRP concentration-increase of proliferation (Ki-67 immunofluorescent staining (green), nuclei (DAPI, blue) of ADSC cultured for 4d.



**Figure 2.** PRP promotes cell proliferation in a dose-dependent fashion. B: Quantification of actual total numbers of cells per well or fraction of proliferating ADSC (Ki-67) by automated image analyses (Tissue Gnostics Tissue FAXS) corroborates the qualitative observations. Graphs represent triplicates (with SEM) data from  $n = 3$  independent experiments from 3 PRP donors.

*PRP promotes cell proliferation in a dose-dependent fashion.*

Human ADSC proliferated irrespective of supplemented PRP, PPP or FCS. ADSC had a fibroblast-like appearance (Fig. 2A), with no visual signs of apoptosis such as blebbing. Moreover, both 5% and 15%-PRP had visibly higher cell numbers after 4d of culture (Fig 2A). This dose-dependent influence of PRP on proliferation of ADSC was corroborated by quantification (Fig. 2B). Total cell numbers were increased in media with 15%-PRP ( $p < 0.05$ ), while in media with 5% and 15%-PRP also more proliferating cells were present as observed by increased expression of Ki-67 (Fig. 2B). In contrast, proliferation was hampered in media with 1.7%-PRP, proliferation in media with 15%-PPP and 10%-FCS were comparable.

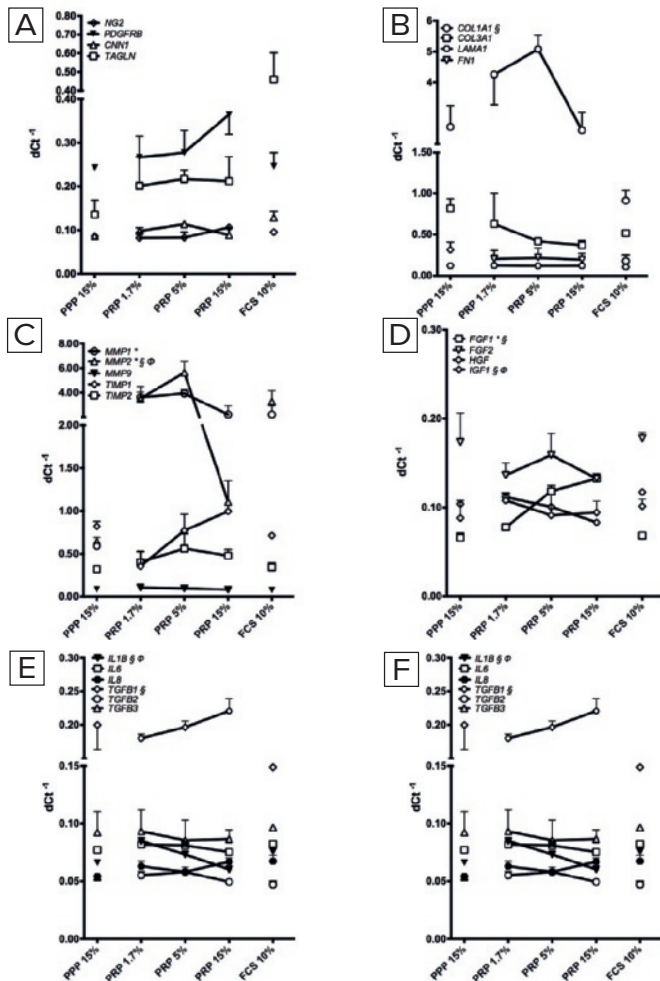
*Gene expression in ADSC is influenced by PRP in a dose-dependent fashion.*

The beneficial function of ADSC relies on the expression of genes that influence angiogenesis, inflammation and remodeling of the extracellular matrix. The expression of representative genes showed a dose-dependent expression to PRP as compared to controls (PPP and FCS, Fig. 3).

Mesenchymal differentiation. All PRP media induced minor changes in TAGLN expression compared to 10%-FCS ( $p > 0.05$ ) and 15%-PPP ( $p > 0.05$ ). Relative gene expression of CCN1 was unchanged (Fig. 3A). On the other hand the pericytic nature of ADSC was stable as expression of PDGFR and NG2 was stable (Fig. 3A)

Matrix remodeling. Expression of COL1A1 increased with PRP-15%, PRP-5% and PRP-1.7% PRP compared to FCS-10% ( $p < 0.05$ ), with a peak at PRP-5%, followed by a decrease at PRP-15% (Fig. 3B). Matrix metalloproteinases MMP1 and MMP2 followed a similar pattern with the highest expression at PRP-5% and 1.7% but unchanged expression in FCS-10% (Fig. 3C). All PRP concentrations increased expression of MMP1 and MMP2 compared to PPP-15% ( $p < 0.05$ ). However, the highest expression of MMP2 was in medium with 10%-FCS compared to medium with to PRP ( $p < 0.05$ ). A strong decrease in gene expression of MMP2 was observed at PRP-15% compared to FCS-10% ( $p < 0.05$ ) and the 5 and 1.7% PRP ( $p < 0.05$ , Fig. 3C). Expression of COL3A1 was unaltered by PRP compared to controls(FCS-and PPP-, Fig. 3B).

Paracrine factors. The expression of TGF- $\beta$  1 increased with increasing PRP concentrations, all concentrations induced a higher expression compared to FCS ( $p > 0.05$ , Fig. 3E). Similarly, the expression of FGF1 followed the concentration of PRP with the highest expression in 15%-PRP.



**Figure 3.** PRP influences gene expression in ADSC in a dose-dependent fashion. Quantitative RT-PCR analysis of gene transcript levels normalized to ACTB expression.

None of the serum or plasma-derived medium additives caused differentiation to smooth muscle-like cells (A – TAGLN, CCN1) nor altered the pericytic nature of ADSC (A – PDGFRB, NG2). Of all four extracellular matrix genes (ECM), COL1A1, COL3A1, LAMA1 and FN1, COL1A1 was downregulated in PRP-media compared to FCS controls (B), In contrast, of the ECM remodeling genes, MMP1, MMP2, MMP9, TIMP1 and TIMP2, MMP2 (a gelatinase) was upregulated in high concentration PRP-medium compared to lower concentrations and to PPP as well as FCS controls (C). While MMP1 was upregulated compared to both PPP-controls (C). Of the pro-mitotic growth factor genes FGF1, FGF2, HGF and IGF1, FGF1 was upregulated compared to both controls, while IGF1 was upregulated compared to FCS controls and showed a PRP-dose-dependent increased expression too (D). Inflammatory genes (IL1B, IL6, IL8, TGFB1, TGFB2 and TGFB3) were not regulated, except for TGFB that was upregulated compared to FCS controls, while IL1B was downregulated in a dose-dependent fashion and compared to FCS controls (E). The pro-angiogenic genes VEGFA and ANGPT2 were both regulated compared to FCS controls, while VEGFA showed a PRP-dose-dependent downregulation too.

Graphs represent triplicates (with SEM) data from n = 3 independent experiments from 3 PRP donors. Significant changes in expression ( $p < 0.05$ ): \* One or more PRP concentration(s) compared to PPP 15%; § One or more PRP concentration(s) compared to FCS 10%; Φ Within PRP concentrations.

Both PRP-15% and 5% increased expression compared to PPP and FCS ( $p < 0.05$ , Fig. 3D). The expression of IL1B decreased in a concentration-dependent manner with increasing PRP concentrations in the medium. In medium with 15%-PRP the expression of IL1B was lower compared to media with FCS-, PRP-5% and PRP-1.7% ( $p < 0.05$ , Fig. 3E). The gene expression of IGF1 followed a similar pattern, with decreased expression at increasing PRP concentrations. At 15%, PRP affected IGF1 expression most compared to FCS-10% ( $p < 0.05$ , Fig. 3D).

Angiogenesis. The expression of VEGFA, as a marker for pro-angiogenic capacity of ADSC, showed a reciprocal relation with increasing concentrations of PRP in the medium (Fig. 3F). While only 1.7%-PRP in medium caused a significant decrease of the expression of VEGFA ( $p < 0.05$ ). ANGPT1 expression was also affected; PRP-15% induced a down regulation compared to FCS-10% ( $p > 0.05$ ), PRP-5% and PRP-1.7% ( $p < 0.05$ ). ANGPT2 showed a small decrease in the PRP conditions compared to PPP-15% and FCS-10% ( $p > 0.05$ , Fig. 3E).

*Dose-dependent influence of PRP on ADSC-induced endothelial sprouting.*

The addition of 1.7, 5 or 15% PRP to endothelial culture medium instead of FCS-20% resulted in the readily formation of a endothelial sprouting network in all concentrations at 6h which lasted for at least 24h (online suppl. Fig. 4B). The number of loops, branches, and branch lengths peaked at PRP-15% after 6h ( $p > 0.05$ , Fig. 4A). Moreover, networks that had formed in ECM-PRP-15% media remained intact for 72h, while in all other conditions the networks had collapsed ( $p < 0.05$ ). Much to our surprise, conditioned medium of ADSC that were cultured in the presence of 5% PRP or 15% PRP, strongly inhibited sprouting of HUVEC in vitro as observed by the absence of loops or branches (Fig. 4A, online suppl. Fig. 4C). Conditioned medium from ADSC cultured medium with PRP-1.7%, however, induced network formation with comparable number of loops and branches to control media conditioned medium PPP-15%, and conditioned medium FCS-10%. ECM-FCS-0% resulted in lowest number of loops and branches ( $p > 0.05$ ).



A

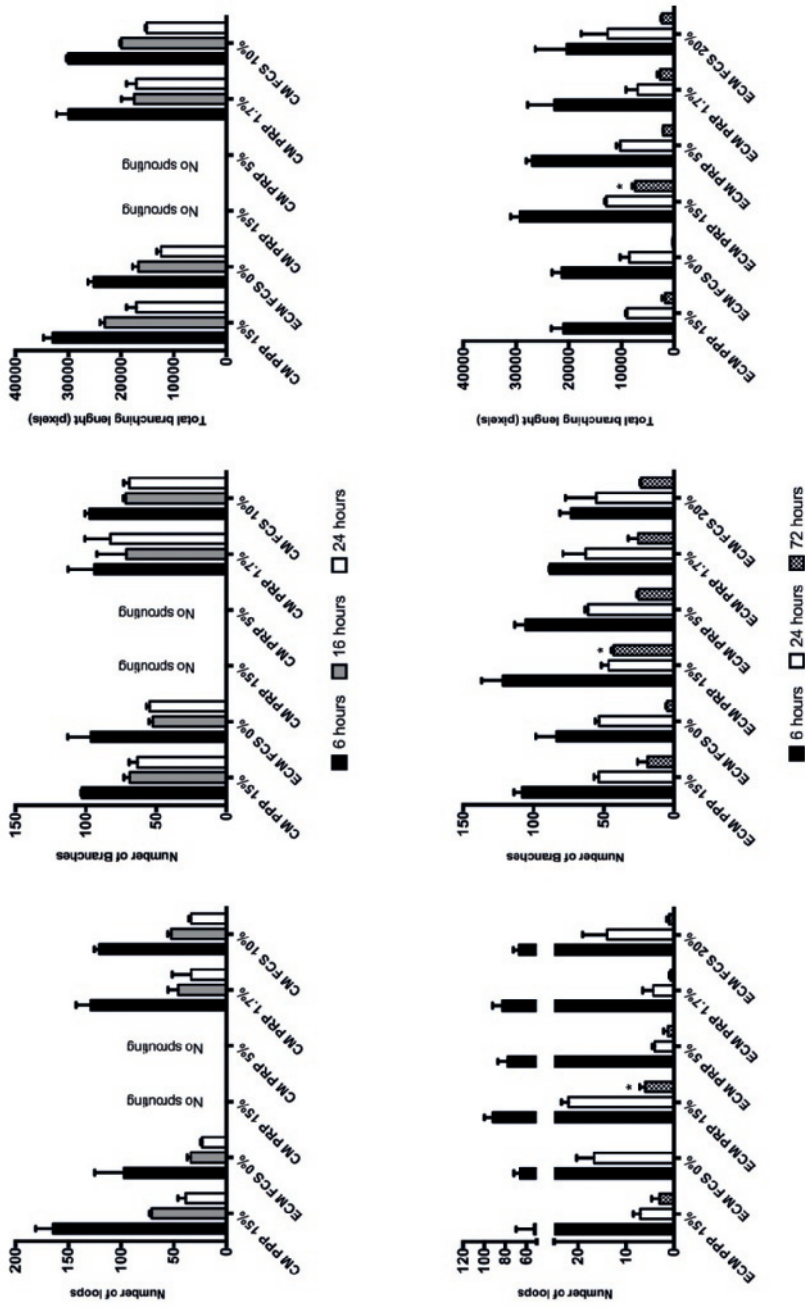
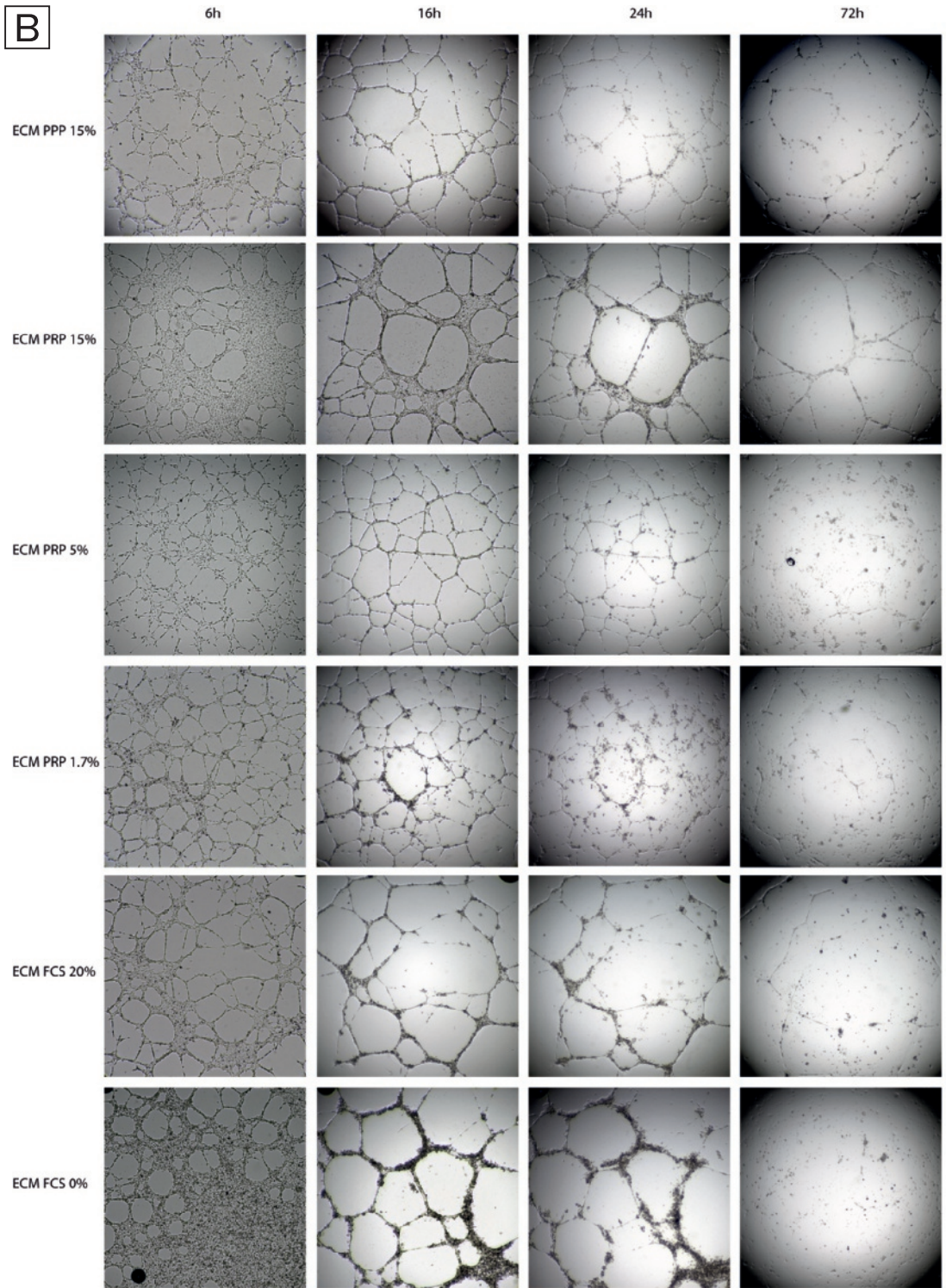



Figure 4. In vitro sprouting of HUVEC is affected by PRP alone and by PRP-conditioned media from ADSC. A. Sprouting networks of HUVEC on Matrigel were readily (6h) formed and remained present at 24h, while only in medium with 15% PRP these networks remained stable for 72h (A and online suppl. B and C). Conditioned medium derived from ADSC cultured in media with 5% PRP or 15% PRP abolished the formation of endothelial sprouting networks as compared to controls (online suppl. C). In general, the presence or absence of plasma or serum constituents did not cause differences in the number of loops, branches and total branching length. The number of sprouts, quantified in number of loops and branches as well as their length, calculated by the Angiogenesis-analyzer plugin for Image J. Significant ( $p < 0.05$ ): \* One or more PRP concentration(s) compared to PPP 15%, FCS 10%. Graphs represent triplicates (with SEM) data from  $n = 3$  independent experiments from 3 PRP donors.



**Figure 4.** *In vitro* sprouting of HUVEC is affected by PRP alone and by PRP-conditioned media from ADSC.  
**B.** Sprouting networks of HUVEC on Matrigel with PRP as serum component. Light micrographs of individual wells of slide angiogenesis plates coated with Matrigel were taken at 2.5x original magnification.



**Figure 4.** *In vitro* sprouting of HUVEC is affected by PRP alone and by PRP-conditioned media from ADSC.  
**C.** Sprouting networks of HUVEC on Matrigel with conditioned medium derived from ADSC cultured in media with 1.7%, 5% PRP or 15% PRP. Light micrographs of individual wells of slide angiogenesis plates coated with Matrigel were taken at 2.5x original magnification.

## Discussion

Our results show that in vitro ADSC respond to Platelet Rich Plasma in a dose-dependent way: PRP caused a dose-dependent increase of the proliferation rate of ADSC, which coincided with increased expression of Ki-67. Moreover, ADSC showed a dose-dependent decrease of several paracrine genes, which is relevant to tissue repair or the take of lipografts. This was corroborated by the near abolished capacity of ADSC to support angiogenic sprouting of endothelial cells in vitro after treatment with high concentrations of PRP which to our knowledge, has not yet been demonstrated thus far.

PRP is used as an additive in various clinical indications<sup>21,33</sup>, including the use of lipografts. It is generally accepted that the growth factors present in PRP, presumed in high concentration too, stimulate wound healing<sup>34,35</sup>, tissue remodeling and revascularization<sup>21</sup> and improve lipograft take<sup>15,17,19</sup>. Clinical evaluation studies on the use of PRP, however, report a large variation of results<sup>18-20</sup>, which might be due to interindividual variations in the composition of PRP – lipograft mixtures. Different concentrations of PRP have shown to induce varying effects on fibroblast, osteoblasts and endothelial cells<sup>24,25,36-38</sup>. With ADSC playing a key role in fat graft survival and tissue rejuvenation<sup>28,39</sup>, the effect of PRP in a possible dose-dependent response on ADSC seems to be crucial. A maximum PRP concentration of 15% was chosen because this is the highest clinically feasible concentration available when using disposable PRP-kits, already requiring 4.5ml of PRP in a 25.5ml lipograft.

Our results demonstrated that PRP is a powerful dose-dependent mitogen for ADSC, with two- to fivefold more cells at high PRP concentrations compared to 'normal' FCS after 4d culture. This finding fits the results of various other studies on PRP induced proliferation of ADSC<sup>40-42</sup> fibroblasts<sup>24,43</sup> and HUVEC<sup>13,36</sup>. In the study of Kølke et al<sup>39</sup>, increasing numbers of ADSC in a lipograft had a positive effect on graft take, although consensus of its effect have not yet been confirmed by others. Positive effects on graft survival could be explained by local support of the ADSC on surrounding cells or due to differentiation<sup>44</sup> of ADSC into adipocytes. ADSC cultured in media with PRP maintain their capability to differentiate into adipocytes<sup>45-47</sup>. Differentiation of ADSC into adipocytes could significantly contribute to end graft volume, as suggested by Kølke et al.

In addition we determined that expression of genes related to ADSC function were altered by exposure to different PRP concentrations, as compared to control media PPP-15% and FCS-10%. These changes found in relative gene expression corroborate data of Amable et al<sup>48</sup>, who explored the effects of human platelet lysate on several stem cell types.

Expression of mesenchymal markers was not influenced by PRP which indicates that in PRP ADSC do not acquire myofibroblast features. This is relevant, because myofibroblasts are related fibrotic tissue processes. However, rather large changes were observed in expression of ADSC function related genes. PRP significantly increased expression of genes encoding COL1A1, MMP1 and MMP2. The increases of these factors indicate that PRP increases capacity of ADSC to facilitate tissue remodelling. Moreover, TGF- $\beta$ 1, FGF1 and IGF1 showed a strong dose dependent upregulation, whereas IL1B and VEGFA a downregulation. The upregulation of the anti-inflammatory TGF- $\beta$ 1 and simultaneous downregulation of the pro-inflammatory IL1B would be beneficial in graft take and wound healing where adverse inflammation could cause graft damage and apoptosis. The upregulation of both strongly mitotic and anti-apoptotic growth factors FGF1 and IGF1 would translate to an improved graft take through stimulation of tissue integration and suppression of apoptosis. Together these changes in expression of genes encoding paracrine factors indicate that ADSC switch from a highly pro-angiogenic

phenotype with modest matrix remodelling capacities, to phenotype that is not in support of angiogenesis, while tissue remodelling is enhanced as well as proliferation and survival of tissue cells. This, however, remains topic of future research.

Changes in gene expression were confirmed by the changes in the effects of conditioned media: ADSC exposed to higher PRP concentrations seem to loose pro-angiogenic properties, as endothelial network formation was blocked by their CM. Possible explanations can be found in the up regulation of TGF- $\beta$  1 combined with a decreased expression of VEGFA. While both TGF- $\beta$  1 and VEGFA are associated with angiogenesis by influencing endothelial cells<sup>49, 50</sup>, changes in their relative availability modify the overall effect and can induce endothelial apoptosis<sup>51</sup>, thus blocking network formation.

In contrast to CM derived from ADSC cultured in higher PRP concentrations, direct addition of PRP did not negatively influence endothelial network formation. Increasing PRP concentrations correlated with the formation of more loops and branches, which survived longer as compared to control conditions. PRP effects on endothelial cells are most likely induced by readily available VEGFA, ANG1-Tie2 signaling and activation of the ERK and phosphatidylinositol-3-kinase–Akt pathways<sup>52,53</sup>. The study of Kakudo et al.<sup>13</sup> reported similar positive findings on endothelial network formation, both in vitro and in vivo.

PRP, or platelet lysates have several advantages over the use of animal-derived serums in cell cultures<sup>40</sup>. Risk of contamination with animal pathogens and proteins is absent which allows for use in human cell therapy. Although PRP allows for rapid cell expansion in vitro, ADSC gene expression and correlated secretome production changes as compared to FCS<sup>45,48</sup>. The reported therapeutics properties of ADSC cultured on FCS<sup>10,21,54</sup> might inadvertently be lost by cultivation on high platelet lysate or high PRP concentrations, and therefore warrants further study of the altered properties.

## Conclusion

Results of this study demonstrate that ADSC respond to PRP in a dose-dependent way, and emphasize the need for further research and optimization in the use of PRP as an additive to lipofilling, ADSC enriched lipofilling, or ADSC cell base therapies. Dose depended effects on proliferation and ADSC function were found, most likely explaining the variable varying clinical results that have been observed thus far. However, it remains unclear if, and how a higher number of ADSC with altered function induced by PRP may and will contribute to graft survival. Also, in vivo interaction between endothelial cells-ADSC-PRP, and the resulting effect on angiogenesis requires further study.

Furthermore, ADSC cultured on PRP differ from FCS cultured ADSC, loosing pro-angiogenic properties. This effect should be taken into account by future studies on ADSC based cell therapies using PRP or platelet lysates as serum.

Table 1. Primer sequences for quantitative reverse-transcriptase polymerase chain reaction

Official GENE Symbol	GENE Alias	Sequence Forward	Sequence Reverse
ACTB	beta-Actin	CCAAACCGGAGAAAGATGA	CCAGAGGGCTACAGGGATAG
GAPDH	G3PD, Glyceraldehyde-3-Phosphate Dehydrogenase	AGCCACATCGTCTAGACAC	GCCCAATACGACCAAAATCC
TGFB1	Transforming Growth Factor Beta 1	ACTACTACGCCAAGGAGGTAC	TGCTTGAACCTTGTCATAGATTTCG
TGFB2	Transforming Growth Factor Beta 2	ATAAAATTCAGCCCAGGTCA	CCAAAAGGGAAGAGATGAAA
TGFB3	Transforming Growth Factor Beta 3	ACACTTGGTTAGACGCCTTC	ACCAAATGAACACACAGGGTCT
TAGLN	Transgelin, SM22a	CTGAGGACTATGGGGTCATC	TAGTGCCCATCATTTCTTGGT
CNN1	Calponin-1, basic-Calponin, SMCC	CCAACCATACACAGGGTGACG	TCACCTTGTTCCTTTTCGTCTT
PECAM1	CD31, endoCAM, GPIIA	GCAACACAGTCCAGATAGTCGT	GACCTCAAACCTGGGCATCAT
VWF	Von Willebrand Factor, Factor 8 (F8)	AGTGAGCCTCTCCGGTGATC	TCACCGGACAGCTTGTAGTA
PDGFB	Platelet-Derived Growth Factor B	CTGCATTTTCCTCTTTGTCTT	TTCTGCCCTTAGAGAGGAGTG
PDGFRB	Platelet-Derived Growth Factor Receptor Beta, CD140b	CCCTTATCATCCTCATCATGC	CCTTCCATCGGATCTCGTAA
ANGPT1	ANG1, Angiopoietin 1	CTACTGGGCCTCCTCTCATA	TCTCAAATGGAGGAAAACCAT
ANGPT2	ANG2, Angiopoietin 2	CAGTTCTTCAGAAAGCAGC	TTCAGCACAGTCTCTGAA
VEGFA	Vascular Endothelial Growth Factor A, Vascular Permeability Factor	CCTGAAATGAAGGAAGAGGA	AAATAAAATGGCGAATCCAA
FGF1	Fibroblast Growth Factor 1, acidic FGF	ACCAAGTGGATTCTGCTTCC	CTTGTGGCGCTTCAAGACT

Official GENE Symbol	GENE Alias	Sequence Forward	Sequence Reverse
FGF2	Fibroblast Growth Factor 2, basic FGF	CTGTACCCCATACAGCAGCAG	CGCCTAAAGCCATATTCATT
COL1A1	COL1, Collagen Type 1 alpha 1	GGGATTCCCTGGACCTAAAG	GGAACACCTCGCTCTCCA
COL3A1	COL3, Collagen Type 3 alpha 1	CTGGACCCCAGGGTCTTC	CATCTGATCCAGGGTTTCCA
MMP1	Matrix Metalloproteinase-1, Collagenase (CLGN)	GCTAACCTTTGATGCTATAACTACGA	TTTGTGGCATGTAGAAATCTG
MMP2	Matrix Metalloproteinase-2, Gelatinase A (GLNA)	GTTCCCTTCTTGTTCAATG	CTTGCCATCCTTCTCAAAGT
MMP9	Matrix Metalloproteinase-9, Gelatinase B (GLNB)	GACGATGACGAGTTGTGGT	GAAGATGAAGGGGAAAGTGG
HGF	Scatter factor, Hepatocyte Growth Factor	GTTTCCCAGCTGGTATATGG	GGTCTTTTCAGGAATTGTGC
CSPG4	Chondroitin Sulfate Proteoglycan 4, NG2	GAGAGGCAGCTGAGATCAGAA	TGAGAAATACGATGCTGCAGGT
IGF1	Insulin-like Growth Factor 1, Somatomedin-C	ACTCGGGCTGTTTGTTTTAC	GTGTGCTTCTTGACGACTTG
IL1B	Interleukin 1 beta,	GGTTGAGTTTAAAGCCCAATCCA	TGCTGACCTAGGCTTGATGA
IL6	Interleukin 6	AGCTCAATAAGAAGGGGCCTA	TGAGAAAACCCTGGCTTAAGTAGA
IL8	Interleukin 8, Granulocyte Chemotactic Protein 1 (GCP1), CXCL8, TNFAIP1	CTTTCAGAGACAGCAGAGCA	ACACAGAGCTGCAGAAAATCA
TIMP1	Tissue Inhibitor of Metalloproteinases 1	CCAGCGTTATGAGATCAAGA	AGTATCCGCAGACACTCTCC
TIMP2	Tissue Inhibitor Of Metalloproteinases 2	GAAGAGCCTGAACCACAGGT	CGGGGAGGAGATGTAGCAC
FN1	Fibronectin, GFND2	TCAACTCACAGCTTCTCCAA	TTGATCCCAAAACCAAACTTT
LAMA1	Laminin Alpha 1	ATGGAAAATGGCACACTCTT	AGACTGGGTGTGGACTTT

## References

1. Coleman SR. Structural fat grafting: More than a permanent filler. *Plastic and reconstructive surgery*. 2006;118:108S-120S.
2. Vaienti L, Soresina M, Menozzi A. Parascapular free flap and fat grafts: Combined surgical methods in morphological restoration of hemifacial progressive atrophy. *Plast Reconstr Surg*. 2005;116:699-711.
3. Tonnard P, Verpaele A, Peeters G, Hamdi M, Cornelissen M, Declercq H. Nanofat grafting: Basic research and clinical applications. *Plast Reconstr Surg*. 2013;132:1017-1026.
4. Choi M, Small K, Levovitz C, Lee C, Fadl A, Karp N. The volumetric analysis of fat graft survival in breast reconstruction. *Plast Reconstr Surg*. 2012.
5. Khouri RK, Eisenmann-Klein M, Cardoso E et al. Brava and autologous fat transfer is a safe and effective breast augmentation alternative: Results of a 6-year, 81-patient, prospective multicenter study. *Plast Reconstr Surg*. 2012;129:1173-1187.
6. Kolle SF, Fischer-Nielsen A, Mathiasen AB et al. Enrichment of autologous fat grafts with ex-vivo expanded adipose tissue-derived stem cells for graft survival: A randomised placebo-controlled trial. *Lancet*. 2013;382:1113-1120.
7. Gentile P, Orlandi A, Scioli MG et al. A comparative translational study: The combined use of enhanced stromal vascular fraction and platelet-rich plasma improves fat grafting maintenance in breast reconstruction. *Stem Cells Transl Med*. 2012;1:341-351.
8. Garza RM, Paik KJ, Chung MT et al. Studies in fat grafting: Part III. fat grafting irradiated tissue--improved skin quality and decreased fat graft retention. *Plast Reconstr Surg*. 2014;134:249-257.
9. Rigotti G, Marchi A, Galie M et al. Clinical treatment of radiotherapy tissue damage by lipoaspirate transplant: A healing process mediated by adipose-derived adult stem cells. *Plastic and reconstructive surgery*. 2007;119:1409-22; discussion 1423-4.
10. Gentile P, Orlandi A, Scioli MG, Di Pasquali C, Bocchini I, Cervelli V. Concise review: Adipose-derived stromal vascular fraction cells and platelet-rich plasma: Basic and clinical implications for tissue engineering therapies in regenerative surgery. *Stem Cells Transl Med*. 2012;1:230-236.
11. Marx RE, Carlson ER, Eichstaedt RM, Schimmele SR, Strauss JE, Georgeff KR. Platelet-rich plasma: Growth factor enhancement for bone grafts. *Oral Surg Oral Med Oral Pathol Oral Radiol Endod*. 1998;85:638-646.
12. Lacci KM, Dardik A. Platelet-rich plasma: Support for its use in wound healing. *The Yale journal of biology and medicine*. 2010;83:1-9.
13. Kakudo N, Morimoto N, Kushida S, Ogawa T, Kusumoto K. Platelet-rich plasma releasate promotes angiogenesis in vitro and in vivo. *Med Mol Morphol*. 2014;47:83-89.
14. Pires Fraga MF, Nishio RT, Ishikawa RS, Perin LF, Jr AH, Malheiros CA. Increased survival of free fat grafts with platelet-rich plasma in rabbits. *J Plast Reconstr Aesthet Surg*. 2010.
15. Oh DS, Cheon YW, Jeon YR, Lew DH. Activated platelet-rich plasma improves fat graft survival in nude mice: A pilot study. *Dermatologic surgery* : official publication for American Society for Dermatologic Surgery [et al ]. 2011;37:619-25.
16. Nakamura S, Ishihara M, Takikawa M et al. Platelet-rich plasma (PRP) promotes survival of fat-grafts in rats. *Annals of plastic surgery*. 2010;65:101-6.
17. Rodriguez-Flores J, Palomar-Gallego MA, Enguita-Valls AB, Rodriguez-Peralto JL, Torres J. Influence of platelet-rich plasma on the histologic characteristics of the autologous fat graft to the upper lip of rabbits. *Aesthetic plastic surgery*. 2010.
18. Salgarello M, Visconti G, Rusciani A. Breast fat grafting with platelet-rich plasma: A comparative clinical study and current state of the art. *Plastic and reconstructive surgery*;127:2176-85.
19. Gentile P, Orlandi A, Scioli MG et al. A comparative translational study: The combined use of enhanced stromal vascular fraction and platelet-rich plasma improves fat grafting maintenance in breast reconstruction. *Stem Cells Transl Med*. 2012;1:341-351.
20. Fontdevila J, Guisantes E, Martinez E, Prades E, Berenguer J. Double-blind clinical trial to compare autologous fat grafts versus autologous fat grafts with PDGF: No effect of PDGF. *Plast Reconstr Surg*. 2014;134:219e-230e.
21. Liao HT, Marra KG, Rubin JP. Application of platelet-rich plasma and platelet-rich fibrin in fat grafting: Basic science and literature review. *Tissue Eng Part B Rev*. 2014;20:267-276.
22. Ramos-Torrecillas J, Luna-Bertos E, Manzano-Moreno FJ, Garcia-Martinez O, Ruiz C. Human



- fibroblast-like cultures in the presence of platelet-rich plasma as a single growth factor source: Clinical implications. *Adv Skin Wound Care*. 2014;27:114-120.
23. Shin MK, Lee JW, Kim YI, Kim YO, Seok H, Kim NI. The effects of platelet-rich clot releasate on the expression of MMP-1 and type I collagen in human adult dermal fibroblasts: PRP is a stronger MMP-1 stimulator. *Mol Biol Rep*. 2014;41:3-8.
24. Kushida S, Kakudo N, Suzuki K, Kusumoto K. Effects of platelet-rich plasma on proliferation and myofibroblastic differentiation in human dermal fibroblasts. *Ann Plast Surg*. 2013;71:219-224.
25. Graziani F, Ivanovski S, Cei S, Ducci F, Tonetti M, Gabriele M. The in vitro effect of different PRP concentrations on osteoblasts and fibroblasts. *Clinical oral implants research*. 2006;17:212-9.
26. Yamaguchi R, Terashima H, Yoneyama S, Tadano S, Ohkohchi N. Effects of platelet-rich plasma on intestinal anastomotic healing in rats: PRP concentration is a key factor. *The Journal of surgical research*. 2010.
27. Kim JH, Jung M, Kim HS, Kim YM, Choi EH. Adipose-derived stem cells as a new therapeutic modality for ageing skin. *Exp Dermatol*. 2011;20:383-387.
28. Trojahn Kolle SF, Oliveri RS, Glovinski PV, Elberg JJ, Fischer-Nielsen A, Drzewiecki KT. Importance of mesenchymal stem cells in autologous fat grafting: A systematic review of existing studies. *Journal of plastic surgery and hand surgery*. 2012;46:59-68.
29. Przybyt E, Krenning G, Brinker MG, Harmsen MC. Adipose stromal cells primed with hypoxia and inflammation enhance cardiomyocyte proliferation rate in vitro through STAT3 and Erk1/2. *J Transl Med*. 2013;11:39-5876-11-39.
30. de Mos M, van der Windt AE, Jahr H et al. Can platelet-rich plasma enhance tendon repair? A cell culture study. *Am J Sports Med*. 2008;36:1171-1178.
31. Burgess WH, Mehlman T, Friesel R, Johnson WV, Maciag T. Multiple forms of endothelial cell growth factor. rapid isolation and biological and chemical characterization. *J Biol Chem*. 1985;260:11389-11392.
32. Carpentier G, Martinelli M, Courty J and Cascone I. Angiogenesis analyzer for ImageJ. 4th ImageJ user and developer conference proceedings. mondorf-les-bains, luxembourg. ISBN: 2-919941-18-6 : 198-201, 2012..
33. Eppley BL, Pietrzak WS, Blanton M. Platelet-rich plasma: A review of biology and applications in plastic surgery. *Plastic and reconstructive surgery*. 2006;118:147e-159e.
34. Cervelli V, Gentile P, Scioli MG et al. Application of platelet-rich plasma in plastic surgery: Clinical and in vitro evaluation. *Tissue engineering*. 2009;15:625-34.
35. Engebretsen L, Steffen K, Alsousou J et al. IOC consensus paper on the use of platelet-rich plasma in sports medicine. *British journal of sports medicine*. 2010;44:1072-81.
36. Mooren RE, Hendriks EJ, van den Beucken JJ et al. The effect of platelet-rich plasma in vitro on primary cells: Rat osteoblast-like cells and human endothelial cells. *Tissue engineering*;16:3159-72.
37. Goedecke A, Wobus M, Krech M et al. Differential effect of platelet-rich plasma and fetal calf serum on bone marrow-derived human mesenchymal stromal cells expanded in vitro. *Journal of tissue engineering and regenerative medicine*;5:648-54.
38. Creeper F, Lichanska AM, Marshall RI, Seymour GJ, Ivanovski S. The effect of platelet-rich plasma on osteoblast and periodontal ligament cell migration, proliferation and differentiation. *Journal of periodontal research*. 2009;44:258-65.
39. Kolle SF, Fischer-Nielsen A, Mathiasen AB et al. Enrichment of autologous fat grafts with ex-vivo expanded adipose tissue-derived stem cells for graft survival: A randomised placebo-controlled trial. *Lancet*. 2013;382:1113-1120.
40. Trojahn Kolle SF, Oliveri RS, Glovinski PV et al. Pooled human platelet lysate versus fetal bovine serum-investigating the proliferation rate, chromosome stability and angiogenic potential of human adipose tissue-derived stem cells intended for clinical use. *Cytotherapy*. 2013;15:1086-1097.
41. Man Y, Wang P, Guo Y et al. Angiogenic and osteogenic potential of platelet-rich plasma and adipose-derived stem cell laden alginate microspheres. *Biomaterials*. 2012;33:8802-8811.
42. Kishimoto S, Ishihara M, Mori Y et al. Effective expansion of human adipose-derived stromal cells and bone marrow-derived mesenchymal stem cells cultured on a fragmin/protamine nanoparticles-coated substratum with human platelet-rich plasma. *J Tissue Eng Regen Med*. 2012.
43. Creeper F, Ivanovski S. Effect of autologous and allogenic platelet-rich plasma on human gingival fibroblast function. *Oral diseases*. 2012;18:494-500.
44. Cervelli V, Scioli MG, Gentile P et al. Platelet-rich plasma greatly potentiates insulin-induced

adipogenic differentiation of human adipose-derived stem cells through a serine/threonine kinase akt-dependent mechanism and promotes clinical fat graft maintenance. *Stem Cells Transl Med.* 2012;1:206-220.

45. Bieback K. Platelet lysate as replacement for fetal bovine serum in mesenchymal stromal cell cultures. *Transfus Med Hemother.* 2013;40:326-335.

46. Blande IS, Bassaneze V, Lavini-Ramos C et al. Adipose tissue mesenchymal stem cell expansion in animal serum-free medium supplemented with autologous human platelet lysate. *Transfusion.* 2009;49:2680-2685.

47. Scioli MG, Bielli A, Gentile P, Mazzaglia D, Cervelli V, Orlandi A. The biomolecular basis of adipogenic differentiation of adipose-derived stem cells. *Int J Mol Sci.* 2014;15:6517-6526.

48. Amable PR, Teixeira MV, Carias RB, Granjeiro JM, Borojevic R. Mesenchymal stromal cell proliferation, gene expression and protein production in human platelet-rich plasma-supplemented media. *PLoS One.* 2014;9:e104662.

49. Ferrara N, Gerber HP. The role of vascular endothelial growth factor in angiogenesis. *Acta haematologica.* 2001;106:148-56.

50. Mallet C, Vittet D, Feige JJ, Bailly S. TGFbeta1 induces vasculogenesis and inhibits angiogenic sprouting in an embryonic stem cell differentiation model: Respective contribution of ALK1 and ALK5. *Stem Cells.* 2006;24:2420-2427.

51. Ferrari G, Cook BD, Terushkin V, Pintucci G, Mignatti P. Transforming growth factor-beta 1 (TGF-beta1) induces angiogenesis through vascular endothelial growth factor (VEGF)-mediated apoptosis. *J Cell Physiol.* 2009;219:449-458.

52. Mammoto T, Jiang A, Jiang E, Mammoto A. Platelet rich plasma extract promotes angiogenesis through the angiopoietin1-Tie2 pathway. *Microvasc Res.* 2013;89:15-24.

53. Mammoto T, Jiang A, Jiang E, Mammoto A. Platelet-rich-plasma extract prevents pulmonary edema through angiopoietin-Tie2 signaling. *Am J Respir Cell Mol Biol.* 2014.

54. Spiekman M, Przybyt E, Plantinga JA, Gibbs S, van der Lei B, Harmsen MC. Adipose tissue-derived stromal cells inhibit TGF-beta1-induced differentiation of human dermal fibroblasts and keloid scar-derived fibroblasts in a paracrine fashion. *Plast Reconstr Surg.* 2014;134:699-712.



---

---

# VI

## THE POWER OF FAT AND ITS ADIPOSE- DERIVED STROMAL CELLS: EMERGING CONCEPTS FOR FIBROTIC SCAR TREATMENT

- 
1. MAROESJKA SPIEKMAN
  2. JORIS VAN DONGEN
  3. JOEP C.N. WILLEMSSEN
  4. DELIA L. HOPPE
  5. BEREND VAN DER LEI
  6. MARTIN C. HARMSSEN

### *Introduction*

Lipofilling or lipografting is a novel and promising treatment method for reduction or prevention of dermal scars after injury. Ample anecdotal evidence from case reports supports the scar-reducing properties of adipose tissue grafts. However, only a few properly controlled and designed clinical trials have been conducted thus far on this topic. Also the underlying mechanism, by which lipofilling improves scar aspect and reduces neuropathic scar pain, remains largely undiscovered. Adipose-derived stromal or stem cells are often described to be responsible for this therapeutic effect of lipofilling.

### *Results*

See conclusion

### *Material and Methods*

We review the recent literature and discuss anticipated mechanisms that govern anti-scarring capacity of adipose tissue and its adipose-derived stem/stromal cells.

### *Conclusion*

Both clinical and animal studies clearly demonstrated that lipofilling and ADSC influence processes associated with wound healing including extracellular matrix remodeling, angiogenesis and modulation of inflammation in dermal scars. However, randomized clinical trials, providing sufficient level of evidence for lipofilling and/or ADSC as an anti-scarring treatment, are lacking yet warranted in the near future.

## Development of lipofilling procedures

Transfer of adipose tissue, also known as fat grafting, lipografting or lipofilling is recognized as a promising and novel technique for correction of volume deficiency, skin rejuvenation and as treatment for scars. This is strongly supported by evidence-based clinical trials as well as fundamental studies in animals and in vitro. The first case of lipofilling in literature dates from 1893, when Gustav Neuber described the first free fat transfer for a scar which had left a young man with a soft tissue defect of the face <sup>1</sup>.

As soon as liposuction was further developed in the mid 1980's, also interest developed of re-using the lipoaspirated subcutaneous adipose tissue. Liposuction pioneers such as Illouz and co-workers <sup>2</sup> developed the first clinical applications and methods for lipofilling to restore or gain volume. The real breakthrough in lipofilling came with fat harvesting, subsequent processing and subcutaneous administration as described by Coleman <sup>3</sup>, which allowed better survival of the lipograft. Centrifugation was the first successful attempt to improve fat graft survival by removing oil, fluid and dead cells from the harvested fat tissue. This method also inspired clinical trials to assess volumetric augmentation of the breast and buttocks <sup>4,5</sup>.

Initially, introduced by Coleman in the early nineties, the use of small liposuction and lipofilling cannulas also opened the door for lipofilling of the face and hands for both reconstructive and aesthetic purposes. Especially in these applications with rather superficial lipofilling, effects described as 'more than volume alone' were often observed <sup>3,6</sup>. This included an improved appearance and quality of the skin and has subsequently been described in many case reports. Yet a mechanistic underpinning was still lacking. These clinical observations initiated a wide range of clinical applications for lipofilling other than just volume adjustment <sup>7</sup>. This novel idea to use lipofilling for treatment of (the consequences of) tissue damage, has led to the use of lipofilling to treat burn scars <sup>8</sup> and even to alleviate scar-associated pain as occurring e.g. after mastectomy <sup>9</sup>.

In 2001, Zuk and colleagues <sup>10</sup> demonstrated that adipose tissue had a source of endogenous mesenchymal stem cells, which were named adipose-derived stem or stromal cells (ADSC). This discovery significantly advanced the use of lipofilling as a regenerative therapy, as it had been shown that at least one of the components of adipose tissue had therapeutic potential. Since then, many of the beneficial effects observed after lipofilling have been attributed to ADSC.

In this review the authors, both clinicians and biologist, try to bridge the gap between both worlds, provide a review of recent literature and summarize possible mechanism behind the anti-scarring effect of adipose tissue and its adipose-derived stem/stromal cells.

## Lipofilling on a cellular level

Liposuction simply implicates the harvest of adipose tissue under negative pressure with small-bore suction cannulas. By this, the architecture of the fat tissue is disrupted and small lumps of adipose tissue are harvested and collected in a sterile environment (bag or collector), which can then be used for lipofilling subsequently. Inevitably, some degree of hypoxia occurs around the grafting of the lipoaspirate. In the recipient, the integration of the graft requires extensive (re)vascularization, which is primed by the occurring hypoxia as well as by the pre-existing microvasculature in the graft. Too large 'lumps' of lipograft obviously develop necrotic cores due to diffusion insufficiency, as a result of which the graft 'take' may be reduced <sup>11-13</sup>.

Adipocytes are sensitive to hypoxia and as a consequence prone to apoptosis<sup>11,12,14</sup>. Depending on the technique and time that is required for harvesting and lipofilling<sup>15,16</sup>, 40-90% of the injected lipograft volume will remain<sup>17</sup>, while the rest is resorbed within months after grafting. Oily cysts may remain in the grafted area as a consequence of this fat necrosis. To improve fat graft survival, different processing techniques are used (e.g. centrifugation, decantation, gauze-towel technique). In a systematic review, these techniques are compared for viability of the fat graft as a whole<sup>18</sup> in terms of number of viable cells and in terms of graft volume survival in human and animal models. For fat graft survival, the gauze-towel processing technique is found to be superior to centrifugation or decantation. However, if the focus lies on the number of ADSC in adipose grafts, centrifugation improves the number of ADSC that can be isolated, compared to a non-centrifuged fat<sup>19</sup>. Thus, depending on the goal of lipofilling, different fat processing techniques need to be considered carefully.

Adipose tissue, the energy storehouse of the human body, consists of a parenchymal mass of adipocytes that is structurally supported by connective tissue and perfused by blood vessels. All non-adipocyte tissue is called stroma or stromal tissue. Adipocytes are the main volumetric component of adipose tissue although they only comprise up to 20% of all cells<sup>20</sup>. Adipocytes consist of a thin layer of cytoplasm with an eccentric nucleus, while most of the volume is made up by the large central vacuole in which triglycerides predominantly are stored<sup>21</sup>. During development, adipose tissue is derived from the mesodermal germ layer. The mesenchymal stem cells (MSC) that reside in the mesoderm differentiate into adipocytes to form adipose tissue. However, after the embryogenic formation of adipose tissue, some of the mesenchymal stem or stromal cells remain. In the adult situation, these MSC are the previously mentioned ADSC. In the adipose tissue, ADSC reside around the vasculature<sup>22-25</sup>. Furthermore, ADSC retain the ability to differentiate into adipocytes, thus functioning as a source to regenerate adipose tissue<sup>26</sup>.

## Lipofilling as a method to treat scars

As stated above, lipofilling is beneficial for skin and scar treatment. In recent years, a limited number of retrospective and prospective supported previous anecdotal clinical observation (Table 1).

### *Clinical studies*

Clinical efficacy of lipofilling in scar areas is determined either by improvement of the appearance of a scar, such as size, thickness, stiffness, discoloration of the scar. In the case of painful scars, this effect can also be measured by a decrease in pain. In the first subsection of this summary of clinical studies, the focus lies on the ability of lipografts to improve several of the above mentioned appearance of scars, whereas in the second subsection focus lies on the ability to reduce pain.

### *Scar appearance*

Macroscopically, scars are characterized by different appearance than the surrounding skin: discoloration, stiffness and roughness are features of scarring. In clinical studies, different outcome measures are used to quantify the degree of scarring on a macroscopic level. The first method often used to assess scar severity are patient or observer rated grading scales, in which several aspects of scarring (e.g. color, stiffness, thickness, irregularity) are rated. A second method is to use measuring devices for skin elasticity or dermal pigmentation.

The efficacy of lipofilling to improve scar appearance has been investigated in sixteen case reports or clinical trials<sup>6,8,27-38</sup> (see Table 1a). In ten studies of these publications, comprising of a total of 156 patients, complications were recorded: in nine of these ten studies, no complications were recorded whereas in one study with 12 patients there was a case of cellulitis reported as a complication. Hence, it seems that risks of lipofilling in scar areas is rather low. All fourteen case reports or clinical trials reported some degree of amelioration in scar appearance after lipofilling: in other words, scars became less different from normal skin and/or became less visible. However, overall result of these clinical studies is not unequivocal. Firstly, not all studies use the same outcome measurements to report scar appearance: most studies used patient satisfaction or patient and observer rated grading scales for scar severity to report the effect of lipofilling, whereas other studies used measuring devices for skin elasticity or dermal pigmentation. Secondly, whether or not there is improvement in scar appearance varies within these studies: some studies report improvement in most patients, contrasted by no effect in a few other patients. Lastly, also, within the same study, improvement after lipofilling in one outcome measure (e.g. less stiffness of the scar) is reported, but there is no improvement in other outcome measures (e.g. no improvement in discoloration). Thus, the overall trend is that lipofilling improves scar appearance in several different outcome measures, which is confirmed by two systematic reviews<sup>39,40</sup>. However, due to lack of uniformity in intervention and follow up, no definitive conclusions can be drawn.

Only five well designed controlled studies had well-defined objectives and outcome parameters and had included both non-treated<sup>27,34,37</sup> or placebo<sup>29,31</sup> controls. Four of these studies focused on clinical outcomes<sup>27,31,34,37</sup> and are discussed below and one addresses histological changes<sup>29</sup> and is discussed in the next section. In two studies, performed under supervision of the same senior researcher<sup>27,37</sup>, the effect of lipofilling as adjuvant procedure to reduce formation of new scars after surgery is evaluated. During primary cleft lip repair surgery, efficacy of lipofilling is examined by comparison of pre- and post-operative pictures for residual cleft stigmata by a blinded reviewer panel. Compared to primary cleft lip repair without lipofilling, it resulted in significantly less residual cleft stigmata and thus in better scar appearance. Apparently lipofilling led to reduction of scar formation. Also already existing scars can be treated by means of lipofilling: in prosthetic breast reconstruction in the setting of post mastectomy radiotherapy, post-radiotherapy lipofilling can reduce the degree of capsular contracture as measured by the Baker classification<sup>34</sup>. Here, lipofilling apparently is able to prevent or even (partially) revert the fibrotic process of capsular contracture. Another example is the treatment of post-surgical scars in patients with achondroplasia that require surgical limb lengthening<sup>31</sup>. In this study, lipofilling was compared to saline injection: lipofilling significantly increased skin pliability and all but one parameter of the patient and observer scar assessment scale improved. Thus, lipofilling apparently improves appearance of existing scars.

### *Pain reduction*

Efficacy of lipofilling as a means for pain reduction was investigated in six case reports or studies<sup>7,9,41-45</sup> (see Table 1b). No complications were recorded in six of seven studies with a total of 204 patients; one study did not mention any complications. All studies reported a significant reduction of pain after treatment of painful scars: only in two of these studies there was no difference found in one<sup>7</sup> and in two<sup>41</sup> patients out of the entire population. Three studies included control groups, where lipofilling was compared to no treatment<sup>9,42,43</sup>. Two of these studies, performed at the same institute, focused on lipofilling as treatment for neuropathic pain after total mastectomy<sup>9</sup> or breast conserving surgery<sup>42</sup>.



In both studies, it was shown that lipofilling can reduce pain as measured on a visual analogue scale by approximately 3 points in the lipofilling group, compared to about 1 point in the control group. The third study compared results with a representative patient cohort: women who have undergone breast reconstruction

and irradiation after mastectomy<sup>43</sup>. In the lipofilling group there was a significant improvement of all parameters of the LENT-SOMA classification (pain, telangiectasias, breast edema, atrophy and fibrosis) after treatment. For unknown reasons, the authors did not compare and analyze the treatment group with a control group, still but they concluded that lipofilling leads to pain relief as well as amelioration of scar appearance.

### *Influence of lipofilling in scars at the tissue level*

Microscopically, scars display a loss of rete ridges, sebaceous glands and hair follicles. Also, they are characterized by increased dermal and epidermal thickness<sup>46,47</sup>. The epidermal thickening is caused by excessive proliferation of keratinocytes. In the dermis, the thickening is caused by excessive ECM production by myofibroblasts, mainly consisting of collagen type I<sup>48</sup>. Not only is there an increase in the amount of collagens, but also in the collagen fiber thickness, maturation and degree of disorganization<sup>46,47</sup>. Even though there is an increase in the amount of ECM in scarring, some components of normal skin (e.g. elastin, decorin) are less abundant in scars<sup>49</sup>.

In two patient studies, skin biopsies have been acquired before and after treatment of scars with lipofilling<sup>8,29</sup>, one study evaluating a complete series of biopsies from a single patient<sup>8</sup>. After lipofilling, the general structure of the skin improved, collagen was remodeled, and there was an increase in vascularization.

In a large, placebo-controlled study, lipofilling in large burn scars was compared to saline injection<sup>29</sup>. In 96 patients, half of the scar was injected with saline (placebo or sham treated group), the other half was injected with lipoaspirate. Skin biopsies were taken and analyzed after three and six months. Overall, the histological structure of the scars returned near to that of normal skin: a better organization and alignment of collagen fibrils, better vascularization of the dermal papillae, less melanocytic activity in the epidermis and an increase of the amount of elastin fibers. On cellular level, there was an increase in cell divisions in the basal layer of the epidermis and Langerhans cells migrated downwards into this basal layer. Also, levels of pro-fibrotic factor Transforming Growth Factor beta 1 (TGF- $\beta$ 1) and pro-angiogenic factors Vascular Endothelial Growth Factor (VEGF) decreased.

In summary, histological improvement in scar appearance was noted in both studies, expressed as a plethora of changes on both histological as well as cellular level. However, why and how lipofilling results in the improvement of all these aforementioned aspects of scarring including pain reduction, remains to be elucidated.

Table 1a Clinical studies on lipofilling to improve scar appearance

Reference	Study type	Study population	Intervention	Follow-up	Results	Complications
Balkin et al. 2014	Retrospective, controlled	Patients with cleft lip repair (n=30, 37 sides), immediately treated.	Intervention: submuscular, subcutaneous, intra-muscular and peritostal lipofilling (n=10) Control: no lipofilling treatment (n=10)	Photographic analysis by 3 independent observers using a 5-grade scale (mean follow-up of 24.7 months).	Less cleft lip related deformity in overall facial, upper lip, nose and midface appearance in treated group.*	No complications reported
Baskin et al. 2015	Case-report	1 Patient with scarring of the lower extremity after trauma.	Intervention: subcutaneous lipofilling (2 interventions)	Visual evaluation of the lower extremity.	Patient's noted improvement in mobility and appearance, less neckalgia pain.	No complications reported
Bollero et al. 2014	Prospective, non-controlled, non-blinded, randomized	Patients with scars after trauma (n=19).	Intervention: subcut lipofilling (28 interventions)	Visual evaluation of photographs (pre-operative, 1 month and 3 months postoperative).	Among 28 interventions, 24 showed visual improvement. One case showed improvement initially, but not after 3 months.	No complications reported
Bruno et al. 2013	Prospective, controlled, non-blinded, non-randomized	Patients with burn wound scars (n=93 scars). Mean scar age of 2.3 years.	Intervention: intra- and subcut lipofilling (n=93) Control: saline injection (n=93)	Immunohistochemical analysis of scar biopsies, subjective evaluation using a questionnaire, visual evaluation using the VSS (preoperative and 6 months postoperative).	After 6 months, a decrease in lipophages cells and increase in PES and Ki67** No differences in RFT count, improvements in VSS scores from 41 (preoperative) to 15 (6 months postoperative) and questionnaire scores from 31 (pre-operative) to 95 (6 months postoperative) compared to control.	Not mentioned
Byrne et al. 2015	Retrospective, non-controlled	Patients with burn wounds scars of hand (n=13). Mean scar age of 2.3 years.	Intervention: subdermal lipofilling	Aesthetic, functional and satisfaction scores were assessed using the GSM (Dynamometer), DASH, MHQ and POSAS after 31 months (range 3 months – 13 years)	The mobility improved*, but there was no grip strength and DASH improvement. A trend towards significant improvement in MHQ scores was noticed. A significant improvement in the POSAS scores was visible, except the scores for pain and itch.	No complications reported
Coleman et al. 2006	Case-report	1 patient with chronic acne scars.	Intervention: subdermal lipofilling	Visual evaluation of photographs (pre-operative, 1 month and 3 years and 7 months postoperative).	Visual improvement in skin quality.	Not mentioned
Gulianes et al. 2012	Cases-report	Patients with retractile and dystrophic scars (n=8)	Intervention: intracar lipofilling depending on treated area (f interventions)	Photographic analysis by 2 independent observers using a visual 4-grade scale (mean follow-up of 18 months).	Improvement in skin quality, 5 cases obtained a score of 4 and 3 cases obtained a score of 3.	No complications reported
Kilger et al. 2008	Cases-report	Patients with scars as a result of hemifacial 2nd and 3rd degree burns (n=3). Scar age of 2, 3 and 13 years.	Intervention: dermal, hypodermal junction lipofilling (2 interventions per patient)	Histological evaluation of scar biopsies and MRS (preoperative, 13 months postoperative during operation 2, 3 months postoperative).	Histological improvement: patterns of new collagen deposition and more dermal hyperplasia and neoangiogenesis. Presence of annexal structures is nearly normal. MRS revealed similar signal enhancement of scar biopsies before and after lipofilling. No significant reduction occurred in the control group.	Not mentioned
Milone et al. 2014	Prospective, controlled, non-blinded, randomized	Patients with short-limb deformity syndrome present retractile and hypertrophic scars (n=51), managed by surgical procedures (n=36).	Intervention: dermal-hypodermal junction lipofilling (n=36) Control: saline injection (n=36)	A modified POSAS and durometer measurements to measure skin hardness were used (preoperative and 3 months postoperative).	Reduction of all POSAS parameters, except itching in the treatment group. No POSAS scores in control group reported.	No complications reported
Mazzola et al. 2013	Retrospective, non-controlled	Patients who underwent tracheostomy in a healed by secondary intention resulting in a retracting scar (n=11). Scar age of 4-10 years.	Intervention: lipofilling in the plane between skin and subcutaneous tissue, (2 interventions, interval of 6-12 months)	Evaluation of patient satisfaction (mean follow up of 21.3 months)	Patients described functional and aesthetic improvement and were all satisfied. 2 cases with severe retraction needed additional lipofilling procedure.	No complications reported
Pellu et al. 2014	Prospective, non-controlled, non-blinded, randomized	Patients with facial scars of different causes (n=35).	Intervention: subcutaneous lipofilling	A POSAS, tissue oxygen saturation, hemoglobin and dermal temperature and dermal spectrometry measurements performed (pre-operative, 1 month, 3 months, 6 months and 12 months follow-up).	Improvement in overall POSAS scores, both patient score and observer score. Early postoperative measurements revealed increased hemoglobin levels and reduced microcirculation, but both normalized after 7-80 days.	No complications reported
Phulpin et al. 2009	Retrospective, non-controlled	Patients with aesthetic subcutaneous scars (n=32). Lipofilling performed 6 weeks after PMRT.	Intervention: deep and superficial subcutaneous lipofilling	Aesthetic and functional scores were measured (mean follow-up of 35.9 months).	Skin scoring tests revealed more softness, more pliability and better skin quality of the irradiated skin. No scores mentioned.	No complications reported
Ruffolo et al. 2013	Retrospective, controlled	Patients with bilateral MRM and IIBR + PMRT (n=32). Lipofilling performed 6 weeks after PMRT.	Intervention: deep and superficial subcutaneous lipofilling (n=16) Control: no lipofilling treatment (n=16)	Capilar contracture was measured using a 5-grade scale (mean follow-up of 18 months).	7 complications reported in the control group compared to none in the lipofilling group. Higher capsular contracture rates in the control group compared to the lipofilling group. Patient satisfaction increased, but no scores were mentioned.	No complications reported
Sardesai et al. 2007	Prospective, non-controlled, non-blinded, randomized	Patients with various scar types (n=19). Scar age of >1 year, 8.5 years on average.	Intervention: subcutaneous lipofilling	Dermal elasticity (Cutometer), vascularity and pigmentation (Derma-Spectrometer) measured (pre-operative, 1 month and 6 months follow-up). Preoperative and 12-18 months postoperative.	Increase of dermal elasticity** and no difference in vascularity and pigmentation. Decrease of scar stiffness and thickness in patients' perception.*** Less relief and pliability in observers' perception using the POSAS, VSS, MRS and VAS. No significant differences in vascularity and pigmentation (POSAS and VSS).	Not mentioned
Sardesai et al. 2007	Prospective, non-controlled, non-blinded, randomized	Patients with various scar types (n=19). Scar age of >1 year, 8.5 years on average.	Intervention: subcutaneous lipofilling	Effect of fit grafting on the skin was evaluated by severity of irregularity, quality of skin patterns and visual impact. Overall satisfaction was measured using a 5-grade scale (follow up of 3-44 months).	9 cases scored 4-5 and 3 cases scored 3 on the satisfaction scale after treatment. Improvement in the VSS scores was observed. No scores of hypertrophic scars was observed, started 1 month postoperative and continued to 12 months postoperative. No preoperative scores mentioned.	1 case with cellulitis in the feet and calves
Wang et al. 2013	Retrospective, non-controlled	Patients with bilateral gluteal concave deformities associated with intragluteal injections (n=42)	Intervention: deep, intermediate and superficial layer lipofilling of the gluteal	Photographic analysis by 3 independent observers using a 5-grade scale (mean follow-up of 266 days).	Less cleft lip related deformity in overall facial, upper lip, lip appearance (6 months).*** No significant improvement in cleft lip related deformity in the overall nose area (<6 months) and overall facial and midface area (6- months).	Not mentioned
Zaher et al. 2014	Retrospective, controlled	Patients with cleft lip repair (n=35, 44 sides), immediately treated with lipofilling.	Intervention: submuscular, subcutaneous, intra-muscular and peritostal lipofilling (n=19) Control: no lipofilling treatment (n=16)	Photographic analysis by 3 independent observers using a 5-grade scale (mean follow-up of 26.6 months).	Less cleft lip related deformity in overall facial, upper lip, lip appearance (6 months).*** No significant improvement in cleft lip related deformity in the overall nose area (<6 months) and overall facial and midface area (6- months).	Not mentioned

Abbreviations: VSS = Vancouver Scar Scale, TAM = Total Active Movement, GSM = Grip Strength Measurement, DASH = The Disabilities of the Arm, Shoulder and Hand, MHQ = Michigan Hand outcome Questionnaire, POSAS = Patient and Observer Scar Assessment Scale, MRS = Magnetic Resonance Scar, Ki67 = Modified Ki67 Immunohistochemistry, IIBR = Immediate Intraoperative Breast Reconstruction, PMRT = Post-Mastectomy Radiotherapy, PMPS = Post-Mastectomy Pain Syndrome, VAS = Visual Analogue Scale, Neuropathic Pain Symptom Inventory, MRPQ = McGill Pain Questionnaire, PPI = Present Pain Intensity Index, SSRS = Sabbatberg Sexual Self-Rating Scale

\* Significant difference (p<0.05)  
 \*\* Significant difference (p<0.001)

Table 1b Clinical studies on lipofilling to reduce pain

Reference	Study type	Study population	Intervention	Follow up	Results	Complications
Caviglioli et al. 2011	Retrospective, controlled	Patients with severe scar retraction and PMPS after mastectomy with axillary dissection and radiotherapy (n=13).	Intervention: dermal-hypodermal junction lipofilling (n=7); Control: no lipofilling treatment (n=4).	Pain evaluation using a VAS (mean follow-up of 13 months).	Decrease of pain in treated group compared to untreated group.**	No complications reported
Huang et al. 2015	Prospective, non-controlled, non-blinded, non-randomized	Patients with painful neuropathic scars with persistent symptoms (n=13). Range 3 months - 13 months	Intervention: dermal-hypodermal junction and subcutaneous lipofilling.	Pain evaluation using VAS and NPSI scores (pre-operative, 1 week, 4 weeks and 24 weeks postoperative).	Decrease of VAS and VSS scores after 1, 4 and 24 weeks compared to preoperative scores.** No other comparisons between postoperative measurements performed. No effect in 2 cases.	No complications reported
Klinger et al. 2013	Retrospective, semi-controlled, non-blinded, non-randomized	Patients with retractile and painful scars compromising daily activity (n=20). Scar age of > 2 years.	Intervention: dermo-hypodermic junction lipofilling. Control: saline injection.	Pain and skin quality of the scar was evaluated using the POSAS questionnaire (without control group). Scar hardness was measured using the durometer (with control group). Both after 3 months.	All POSAS scores (patient and observer scores) decreased significantly except for itching. Scars hardness decreased postoperative compared to preoperative in the treated group.* No significant decrease of scar hardness	No complications reported
Maione et al. 2014	Prospective, controlled, non-blinded, non-randomized	Patients with PMPS after lumpectomy and radiotherapy (n=96). Lipofilling performed > 1 year after radiotherapy.	Intervention: dermal-hypodermal junction lipofilling (n=53). Control: no lipofilling treatment (n=37).	Evaluation of spontaneous pain using a VAS (preoperative and 1 year postoperative).	A mean decrease of pain of 3.1 in the treated group and 0.9 in the control group. More decrease of pain in the treated group compared to the control group.**	Not mentioned
Panetiere et al. 2009	Prospective, controlled, non-blinded, non-randomized	Patients with irradiated reconstructed breasts after mastectomy for carcinomas (n=61, 62 breasts).	Intervention: subscar lipofilling (serial interventions till patient was satisfied or result was stable). (n=20) Control: no lipofilling treatment (n=4).	Functional results were evaluated using the LENT-SOMA scoring system, 3 months after the last treatment. Aesthetic results were evaluated using a 5-grade scale.	Scores for pain, telangiectasia, breast edema, atrophy and fibrosis decreased in the intervention group after 3 months.** No significant difference for above mentioned scores compared to the control group after 3 months. Aesthetic outcome improved in the intervention group compared to the control group.*	No complications reported
Rigatti et al. 2007	Prospective, non-controlled, non-blinded, non-randomized	Patients with side effects of radiotherapy with severe symptoms and irreversible function damage (LENT-SOMA scale grade 3 and 4) (n=20). Scar age 1-30 years.	Intervention: purified lipofilling.	LENT-SOMA grading scale scores evaluation (mean follow-up of 30 months).	Reduction of LENT-SOMA grading scale scores.** Improvement observed in all patients, except 1 case.	Not mentioned

Abbreviations: VSS = Vancouver Scar Scale, YAM = Total Active Movement, GSM = Grip Strength Measurement, DASH = The Disabilities of the Arm, Shoulder and Hand, WHO = Michigan Hand outcome Questionnaire, POSAS = Patient and Observer Scar Assessment Scale, MRS = Magnetic Resonance Scan, MRSA = Modified Resection of Scar Assessment Inventory, LBR = Mastectomy-Related Limb-Base Reconstruction, PMRT = Post-Mastectomy Radiotherapy, PMPS = Post-Mastectomy Pain Syndrome, VAS = Visual Analogue Scale, NPSI = NeuroPathic Pain Symptom Inventory, MGPA = McGill Pain Questionnaire, PI = Patient Pain Intensity Index, SSSRS = Sabatini Scar Severity Rating Scale

\* Significant difference (p<0.05)

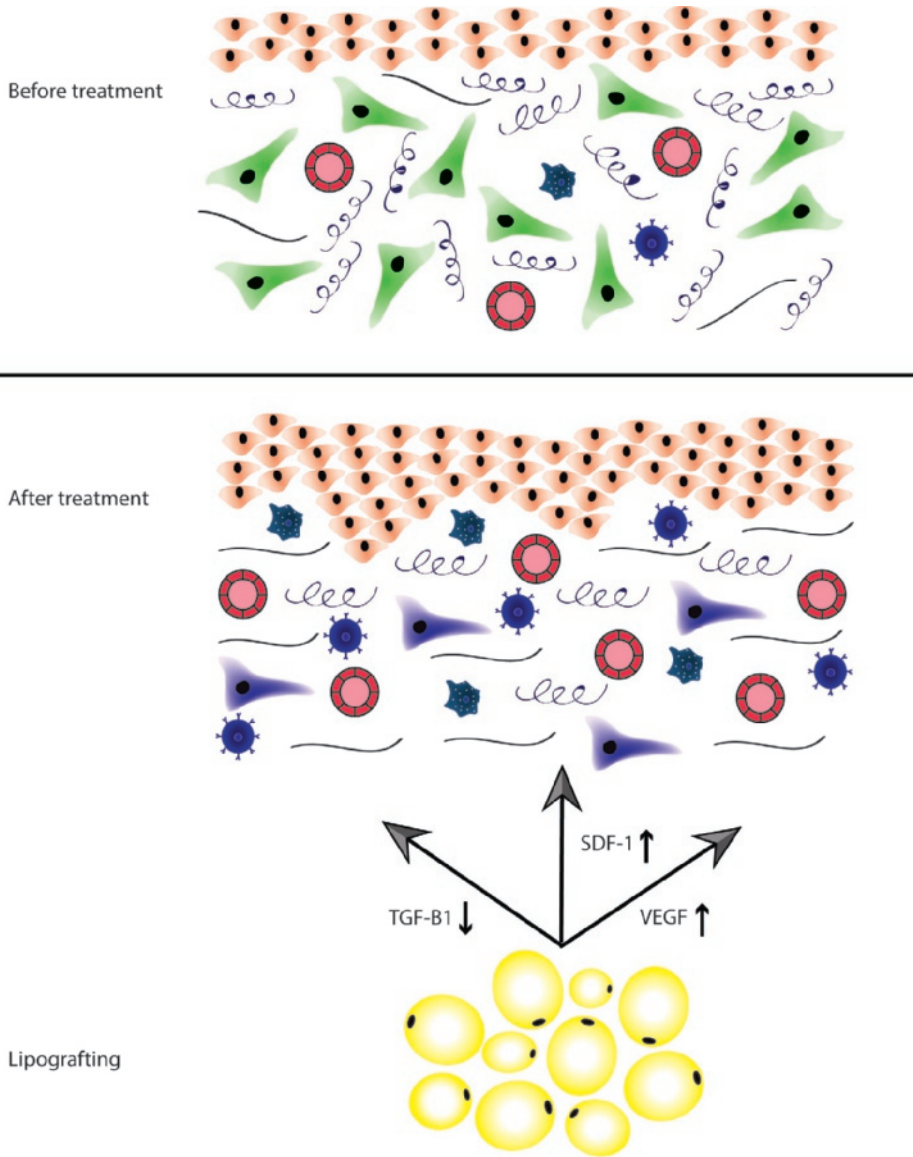
\*\* Significant difference (p<0.001)

### *Animal studies*

In contrast to clinical studies thus far, experimental animal models have been able to demonstrate the mechanisms and influence of lipofilling on dermal scars, scar exterior and scar pain (table 2).

Scar histology has been investigated in two studies using irradiation skin damage models in rodents<sup>50,51</sup> (table 2a). Skin fibrosis after radiation in general is a clinically relevant problem, which can easily be reproduced in rodents. After radiation, dermatitis develops, which eventually gives rise to fibrotic skin characterized by epidermal thickening and irregular deposition of collagen in the dermis. Also, compared to normal skin, irradiated skin areas have an increased vessel density. In two studies in mice, it has been shown that treatment with lipofilling can reduce all these hallmark features of radiation-damaged skin<sup>50,51</sup>. Decrease in SMAD3 protein levels, a key protein in the pro-fibrotic pathway TGF- $\beta$ /Smad signal transduction pathway, partly explains the mechanism of scar improvement<sup>50</sup>. In a slightly different model in mice with full thickness burn wounds, it has been shown that lipofilling leads to better scar appearance by increasing pro-angiogenic factors VEGF and stromal cell-derived factor 1 (SDF-1) and decreasing pro-fibrotic factor TGF- $\beta$ 1<sup>52</sup>. Reduction of neuropathic pain has been reported in two studies of Huang and co-workers<sup>53,54</sup> (table 2b). Allodynia, painful perception of a normally non-painful stimulus, after burn wound injury was tested in rats by means of behavioral testing. After burn injury, lipofilling reduced burn induced allodynia. On the one hand, lipofilling reduces skin fibrosis and scarring after burn injury<sup>53,54</sup> and lowers expression of pro-inflammatory mediators in the skin<sup>54</sup>. On the other hand, lipofilling induces changes in the spinal cord as well decreases microglial activation and by lessens activation of the pro-inflammatory NF $\kappa$ B signal transduction pathway in spinal cord cells

It can be concluded that lipofilling in rodent models for skin injury and fibrosis, reduces adverse fibrotic changes. This appears to be mediated by factors from the lipograft that can inhibit activation of both fibrotic and inflammatory signal transduction pathways. All changes caused by lipofilling in a dermal scar have been drawn schematically in Figure 1.



Legend










- |   |                |   |                     |   |           |
|---|----------------|---|---------------------|---|-----------|
|  | Keratinocyte   |  | Angiogenesis        |  | Collagen  |
|  | Myofibroblasts |  | Monocyte/Macrophage |  | Elastin   |
|  | Fibroblast     |  | Lymphocyte          |  | Adipocyte |

Figure 1. Schematic overview of dermal scar on tissue level, before and after treatment with lipofilling.

## Therapeutic mode of action of ADSC

### *ADSC: stem or stromal cells?*

Because of their ability to differentiate into different cell types, ADSC are sometimes referred to as adipose stem cells. However, a true stem cell has the potential to differentiate into other cell types, while maintaining a stable population of stem cells by the process of self-renewal<sup>55</sup> with indefinite proliferation capability due to telomerase activity<sup>56</sup>. Embryonic stem cells are an example of such pluripotent stem cells: they can undergo an infinite number of cell divisions and can differentiate into all cell types of the three germ layers during embryonic development<sup>57</sup>. ADSC, on the other hand, are a type of adult stem cell that have no telomerase activity and therefore have a limited capacity of proliferation<sup>58</sup>. ADSC can only differentiate into a limited number of cell types, which makes them multipotent progenitor cells. Hence, in the case of ADSC, the authors prefer to speak of adipose-derived stromal cells instead of adipose-derived stem cells.

### *Isolation*

ADSC can be isolated either from intact adipose tissue or from lipoaspirates. The adipose tissue or lipoaspirate is subjected to enzymatic digestion using proteases such as collagenase, dispase or trypsin<sup>10,59-61</sup>. After digestion, the Stromal Vascular Fraction (SVF) that contains ADSC as well as several other cell types, is separated from the mature adipocytes by differential or density gradient centrifugation<sup>10,59-61</sup>. For cell culture, the SVF is then seeded into cell culture dishes. Only ADSC adhere to the tissue culture plastic, whereas other, non-adherent cell types such as erythrocytes, endothelial cells and immune cells, are removed by washing<sup>60</sup>. Then, the remaining ADSC are culture-expanded or cryopreserved until further use.

### *ADSC in vivo versus in vitro*

Adipose tissue contains two major components: SVF and adipocytes. SVF is a heterogeneous mix of cells of eleven main subpopulations based on CD-surface marker expression: seven adipose derived populations (CD45-) and four blood derived populations (CD45pos)<sup>61</sup>. Three important subpopulations of CD45min cells are pericytes (in vivo: CD34<sup>pos</sup>/CD34<sup>min</sup>/CD146<sup>pos</sup>/CD31<sup>min</sup>), supra adventitial cells (in vivo: CD34<sup>pos</sup>/CD146<sup>min</sup>/CD31<sup>min</sup>) and ADSC (in vivo: CD34<sup>pos</sup>/CD90<sup>pos</sup>/CD31<sup>min</sup>/CD105<sup>low</sup>) in a very low number<sup>61-64</sup>. Pericytes and supra-adventitial cells are both identified as precursor cells of ADSC, but there remains controversy<sup>22,23,62,63</sup>.

Enzymatic isolation and culture of those precursor cells or ADSC results in a large series of cells that can be used in regenerative medicine. After several days of culture the in vivo phenotype of precursor cells changes into an in vitro specific phenotype. Most of the cells will lose their CD34 expression and almost all of the cells gain expression of CD105<sup>61,62</sup>. The CD105 marker is also known as endoglin and is a TGF- $\beta$  type III receptor, which is expressed on virtually all cells of mesenchymal origin, but also on e.g. endothelial cells. Ten to twenty percent of the subpopulations remain CD34<sup>pos</sup>, but their proliferation rate and adipogenic differentiation ability is significantly lower as compared to the CD34<sup>min</sup> subpopulation<sup>61,63</sup>. This suggests that 80%-90% of the so-called ADSC, characterized by their phenotype in vitro (CD34<sup>min</sup>/CD105<sup>pos</sup>), are not present in vivo: in other words: the majority of ADSC acquire their phenotype through culturing. Culturing of ADSC also causes dramatic shifts in secretome, as will be discussed within a few sentences below. The different components and cell types of all fractions of adipose tissue are summarized in Figure 2.

**Table 2a Animal studies on lipofilling to improve scar appearance**

Reference	Animal model	Intervention	Follow up	Results
Garza et al. 2014	Mouse Radiation of scalp skin	Treatment: lipofilling (human adipose tissue) 4 weeks after irradiation. Control: no lipofilling and/or no radiation	Histology of skin for epidermal thickness (H&E), collagen arrangement (picosirius red) and vessel density (CD31), CT for fat graft retention. Histology of fat graft. Assessments 2 and/or 8 weeks after lipofilling.	Return of dermal thickness to normal level. Decrease in collagen level to normal level. Increase of vascular density. All for irradiated skin treated with lipofilling, compared to non-treated irradiated skin. Less fat graft retention in irradiated group compared to non-irradiated group.
Sultan et al. 2011	Mouse Full thickness burn wound on dorsum	Treatment: lipofilling (human adipose tissue) 2 weeks after injury. Control: saline injection	Blood flow measurement by Laser-Doppler. Photographs. Histology for collagen arrangement (picosirius red) and vessel density (CD31). Gene and protein expression analysis of skin. Assessment 4 and/or 8 weeks after lipofilling.	Improvement in color and texture of wound area. Increased blood flow in wound area at 4 but not at 8 weeks. Increase in pro-angiogenic proteins and decrease of pro-fibrotic proteins. Increased vessel density at 4 weeks. Better collagen alignment at 8 week. All for lipofilling versus control group.
Sultan et al. 2011	Mouse Radiation of dorsum skin	Treatment: lipofilling (human adipose tissue) 4 weeks after irradiation. Control: saline injection and/or no irradiation	Photographs. Histology for epidermal thickness (H&E), collagen arrangement (picosirius red), vessel density (CD31) and pro-fibrotic marker (Smad3). All at 4 and/or 8 weeks after lipofilling.	Decrease in radiation ulcer size and less hyperpigmentation. Less epidermal thickening. Normalization of vascular density. Decrease in amount of Smad3 (activation not measured). All outcomes for lipofilling treated irradiated animals compared to saline treated irradiated animals.

**Table 2b Animal studies on lipofilling to reduce pain**

Reference	Animal model	Intervention	Follow up	Results
Huang et al. 2014	Rat Full thickness burn wound of hind paw	Treatment: lipofilling (rat adipose tissue) 4 weeks after injury. Controls: saline injection or no treatment, and/or sham burn wound.	Behavioral testing for neuropathic pain: paw withdrawal test with mechanical and heat stimuli. Histology of hind paw skin (H&E, MTC) and of spinal cord (microglial activation). All at 4 weeks after lipofilling.	Reduction of burn induced allodynia. Improvement of skin histology in burn wound treated with lipofilling: decrease in collagen deposition, increased cellularity. Less microglial activation in spinal cord. All observations for burn wounds treated with lipofilling, compared to saline injection.
Huang et al. 2015	Rat Full thickness burn wound of hind paw	Treatment: lipofilling (human adipose tissue) 2 weeks after injury. Control: saline injection	Behavioral testing for neuropathic pain: paw withdrawal tests. Assessment of inflammatory markers in hind paw skin (COX-2, iNOS, nNOS) and spinal cord (IL-1 $\beta$ , TNF $\alpha$ , p-I $\kappa$ B and p-NF $\kappa$ B). All at 4 weeks lipofilling.	Reduction of burn induced allodynia. Decrease of inflammatory markers in hind paw skin and in spinal cord. Decrease in inflammatory pathway activation (p-I $\kappa$ B and p-NF $\kappa$ B) and in pro-apoptotic pathway activation (p-JNK) in spinal cord. All for burn wounds treated with lipofilling, compared to saline injection.

Abbreviations: H&E = hematoxylin and eosin, MTC = Masson's trichrome, IL-1 $\beta$  = interleukin 1 beta, COX-2 = cyclo-oxygenase 2, TNF $\alpha$  = tumor necrosis factor alpha, CD31 = cluster of differentiation 31, iNOS = inducible nitric oxide synthase, nNOS = neuronal nitric oxide synthase

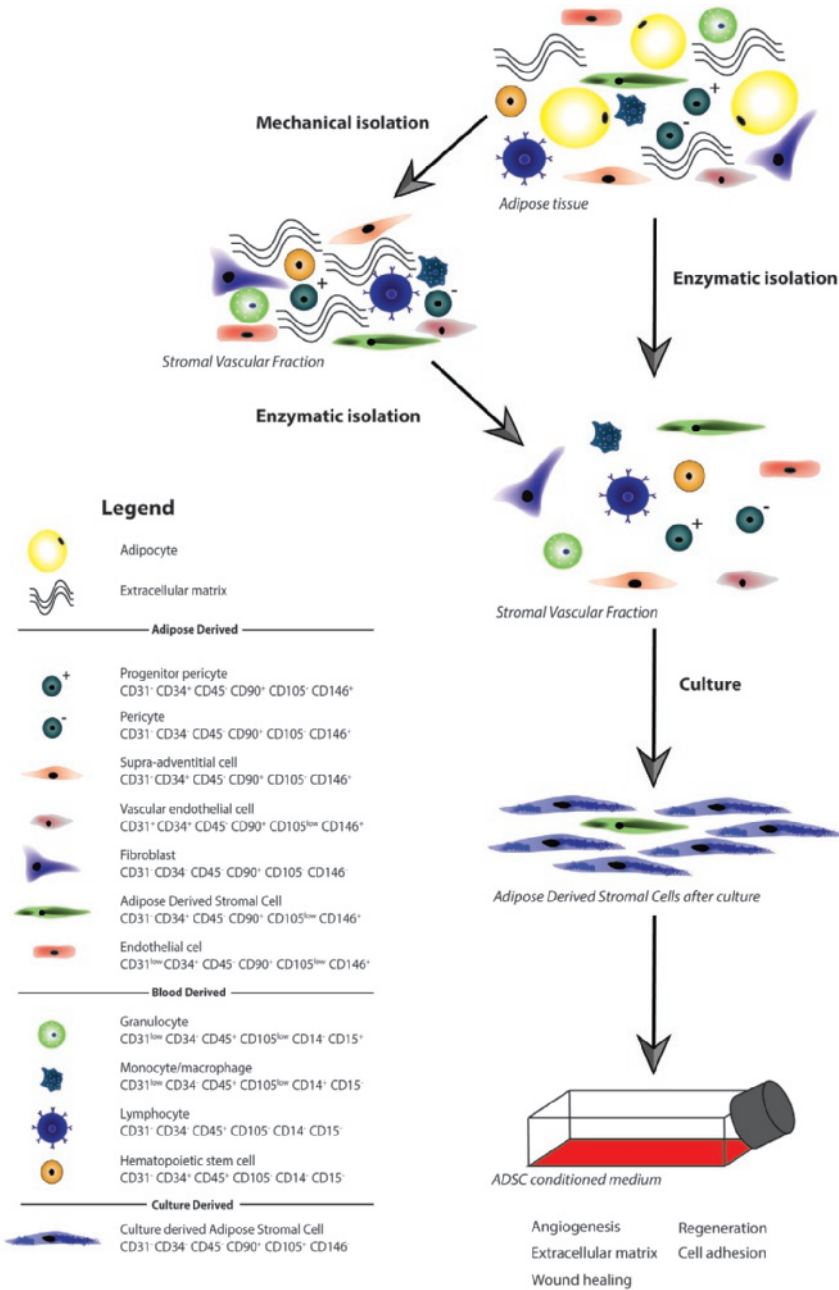


Figure 2. Summary of different fractions of adipose tissue before, during and after mechanical or enzymatic isolation of ADSC. Cell types and their cell surface markers are represented for all different fraction.



Some studies have described that regenerative potencies of ADSC is caused by secretion of trophic factors or differentiation into other cells<sup>65</sup>. In vivo, little is known about the secretion of trophic factors by ADSC. In vitro, secretion of trophic factors by ADSC in medium (called ADSC conditioned medium) is affected by many aspects: differences in culture conditions, donors, methods and medium and cell counts results in different expression of growth factors. For instance, hypoxia culture upregulates VEGF, platelet derived growth factor, placental growth factor and insulin-like growth factor II<sup>66</sup>. A 3D culture structure results in thousands of genes with a significant higher mRNA expression related to extracellular matrix (ECM), cell adhesion, wound healing and growth factors as compared to a 2D structure<sup>67</sup>. Concentrations of proteins related to angiogenesis, ECM remodeling and regeneration increase as well<sup>67</sup>.

The regenerative potency of SVF might be caused by the interaction between cells and growth factors. For example, angiogenesis is significant greater when pericytes and endothelial cells are combined rather than the use of pericytes or endothelial cells alone<sup>68</sup>. Growth factors like VEGF, hepatocyte growth factor and TGF- $\beta$  and extracellular matrix (ECM) stimulate angiogenesis<sup>69</sup>. ECM influences morphogenesis and migration speed depends on ECM density during angiogenesis<sup>70</sup>. Furthermore, ECM functions as a scaffold for other cell types at the site of injection. The interaction of cellular integrins, i.e. matrix receptors, suppresses pro-apoptotic signaling. Thus, applications that include intact, non-enzymatic, generated SVF might favor graft survival. However, only mechanical isolation of SVF preserves ECM, while enzymatic isolation of SVF disrupts all communicative connections between cells. As compared to cultured ADSC and in vitro studied growth factors, freshly isolated SVF contain cells with still their in vivo phenotype and growth factor secretion respectively. As compared to lipofilling, the use SVF might avoid possible complications like cyst formation or overfilling<sup>71</sup>: because only small volumes (less than ten milliliters) of SVF are injected. Thus, since injected volume is limited, there is no risk of overfilling. Since no adipocytes are injected, there is also no risk of oily cyst formation.

## **ADSC as an anti-scarring treatment**

### *Clinical studies*

To date, the use of ADSC as a cell therapy for treatment for fibrosis has not been thoroughly investigated in clinical studies. ADSC have been applied in two non-controlled, non-randomized studies investigating the effect of ADSC-enriched lipografts on healing of chronic, intractable radiation ulcers in 10 patients<sup>72</sup> and for correction of soft tissue defects in 29 patients<sup>73</sup>. It was concluded that ADSC improve wound healing<sup>72</sup> and fat graft take<sup>73</sup> and concomitantly decrease deep tissue fibrosis and dermal scarring. However, fundamentally, there is ample evidence for these effects: ADSC increase angiogenesis, can induce mitosis in resident tissue cells and are able to remodel ECM. Based on the design of both studies, no definitive conclusions can be drawn on the effectiveness of the use of ADSC as scar treatment.

On the other hand, studies in the field of cell-assisted lipotransfer (CAL), where lipografts are combined with ADSC in order to improve fat graft survival, there have been several properly designed, controlled clinical trials<sup>74-76</sup> to demonstrate the efficacy of CAL for improvement of lipograft survival over lipofilling alone. In these studies no serious adverse events were reported after injection of autologous freshly isolated<sup>74,75</sup> or culture expanded<sup>76</sup> ADSC. It can be concluded that use of autologous ADSC in patients is safe. These clinical trials warrant the dissection of the underlying mechanism via animal models and in vitro investigations of underlying molecular pathways.

### *Animal studies*

In animal wound healing models, where ADSC were used to speed up wound healing<sup>77-80</sup> it was observed that ADSC reduce severity of scarring after wound closure (Table 3). ADSC improved the wound healing rate in three out of four studies and smaller fibrotic areas remained after wound healing<sup>77</sup>. Yet, the epidermal thickness increased<sup>79,80</sup>, and the gene expression of the pro-fibrotic markers  $\beta$ -smooth muscle actin and TGF- $\beta$ 1 decreased<sup>79,80</sup> while the gene expression of anti-fibrotic fibroblast growth factor and pro-angiogenic VEGF<sup>79</sup> increased. Together, this indicates that in vivo administered ADSC, suppress the formation of dermal scar, through augmented wound healing. The comparison with clinical treatment of pre-existing scars is hampered, because these animal studies more prevent scar formation than revert pre-existing scars.

In animal models specifically designed to study scarring<sup>81,82</sup> and to study the fibrotic disorder of Peyronie's disease<sup>83</sup> (Table 3), it was noted that deposition of extracellular matrix components, such as collagen type I and III and elastin, was decreased after treatment of scars with ADSC. Also, collagen fiber alignment improved in the treated scar areas<sup>81,82</sup>. Functionally, treatment of scars with ADSC lead to smaller scars<sup>81</sup> and less scar elevation<sup>81</sup>. Together, we surmise that the remodeling of the fibrotic matrix in a scar by ADSC is one of the components that governs scar reduction. Interestingly, ADSC are derived from connective tissue (SVF of fat), but appear to act as 'good guys' in contrast to the scar myofibroblasts, which are connective tissue cells too, but 'bad guys'. The ADSC are capable of tilting the balance between ECM deposition and ECM degradation in favor of degradation. Whether this depends solely on matrix influence or also on direct influence on the scar-resident myofibroblast remains to be investigated.

In conclusion, treatment of wounds or mature scars with ADSC in different animal models have shown to result in faster wound healing and reduction of scar tissue on both macroscopic and microscopic level. Thus, use of autologous ADSC to improve wound healing and to prevent or diminish scar tissue in patients, seems to be a very exciting and promising way to go.

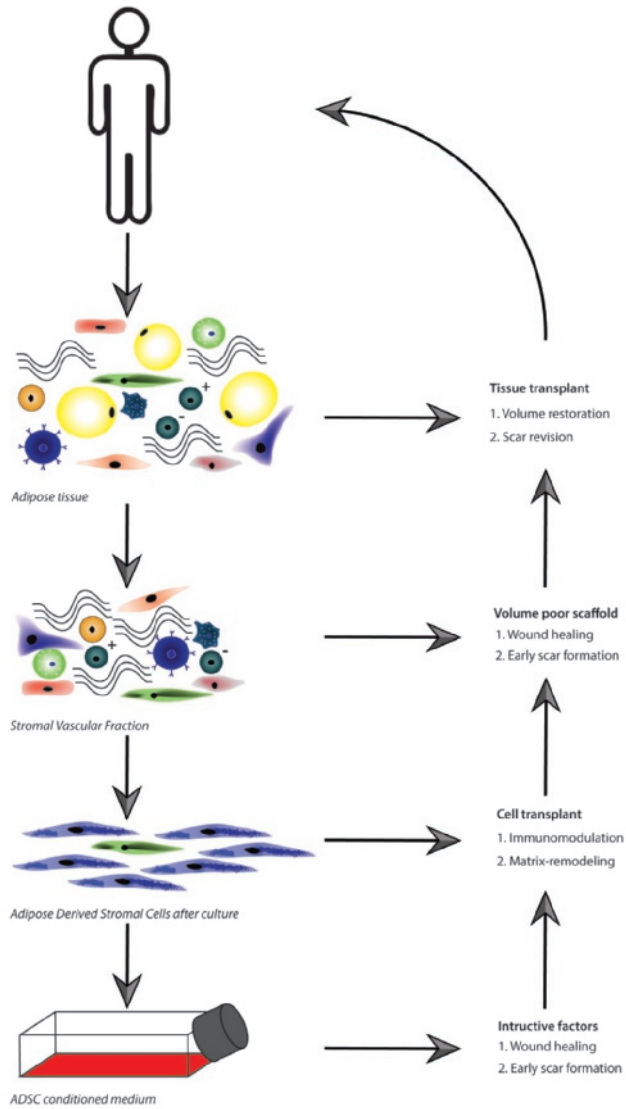
### *In vitro studies*

Myofibroblasts play a major role in wound healing and scarring: activated myofibroblasts proliferate, produce extracellular matrix like collagens and have the ability to contract. After wound healing, myofibroblasts normally are resolved via apoptosis. However, if myofibroblasts persist, scarring will be the end result<sup>84</sup>. In two in vitro studies, it has been shown that trophic factors, produced by ADSC, can inhibit the myofibroblast phenotype of dermal fibroblasts after stimulation with the pro-fibrotic cytokine TGF- $\beta$ 1<sup>85</sup> and can inhibit that of fibroblasts derived from Dupuytren's nodules<sup>86</sup>. Proliferation, extracellular matrix production and contraction of these fibroblasts were reduced, which indicates that growth factors and cytokines of ADSC have the ability to prevent or even to reverse dermal scarring.

**Table 3 Animal studies on ADSC as a treatment for wound healing and scar prevention or reduction**

Reference	Animal model	Biomaterial	Intervention	Follow up	Results
Castiglione et al., 2013	Rat Peyronie's disease (TGF-β1 induced)	No	1x106 labeled human ADSC Control: PB Local injection	Protein expression and histomorphometric analysis of the penis. Erectile function measurements 5 weeks after ADSC-treatment.	Decrease in collagen III and elastin deposition (immunofluorescence). Improved erectile function. Both in ADSC-treated vs. control group.
Lam et al., 2012	Mouse Splinted excisional wound healing model	SIS	1x106 mouse ADSC on SIS patch Control: patch alone or Topical application of ADSC	Wound healing speed, fibrosis (H&E and MTC staining) after wound healing. Measured at day 14 after wounding.	Wound healing improved slightly with ADSC on SIS. Decreased fibrotic area with topical ADSC and with ADSC on SIS Both compared ADSC on SIS to untreated or SIS alone.
Lee et al., 2011	Nude mouse Splinted excisional wound healing model	Collagen gel	1x106 human ADSC in human dermal fibroblast in collagen gel, or collagen gel alone	Photographs of wound area size 10 days after wounding. Scar size 28 days after wounding (H&E staining).	ADSC collagen gel group had a faster wound closure rate than control, but slower than DF collagen gels. Scar size increased in ADSC and DF collagen gel groups compared to control (based on H&E staining alone).
Uysal et al., 2014	Rat Full thickness excisional wound	No	1x107 labeled rat ADSC Control: 1x107 rat BMSC or PBS Local injection	Wound healing speed. Histology for neovascularization, epithelial thickness (both H&E), immunostaining for cyokeratin, αSMA, FGF, VEGF, TGF-β1, β2 and β3. All at day 56 after wounding.	Increased wound healing speed, neovascularization and epithelial thickness. Lower αSMA, TGF-β1, β2 and β3 and higher FGF and VEGF expression. All outcomes for ADSC and BMSC treated groups vs. control group
Yun et al., 2012	Pig Scarring model, after full thickness wound	No	1x106 labeled human ADSC Control: PBS Three consecutive local injections	Area, color and flexibility of scar. Histological assessment of collagen arrangement (MTC), number of mast cells. Gene expression analysis of scar tissue. All until 50 days after ADSC injection.	Slightly smaller scar area and slightly higher pliability. Higher amount of mature collagen. Lower mast cell count. Lower gene expression of αSMA and TIMP1, higher expression of MMP1. All outcomes for ADSC treated group vs. control group.
Zhang et al., 2015	Rabbit Hypertrophic scar model, after full thickness wound	No	4x106 labeled rabbit ADSC Control: ADSC CM, culture medium, or untreated. Local injection	Histology for scar size and collagen arrangement (H&E and MTC). Gene expression analysis of scar tissue. All until 35 days after ADSC injection.	Less scar elevation. Less deposition and better alignment of collagen. Lower gene expression of αSMA and collagen I. All outcomes for ADSC or ADSC CM treated groups vs. culture medium or untreated groups.

Abbreviations: ADSC = Adipose Derived Stem/Stromal Cell, SIS = Small Intestinal Submucosa, H&E = Hematoxylin and Eosin, MTC = Masson's Trichrome, DF = Dermal Fibroblast, αSMA = alpha Smooth Muscle Actin, FGF = Fibroblast Growth Factor, VEGF = Vascular Endothelial Growth Factor, TGF-β = Transforming Growth Factor beta, BMSC = Bone Marrow Mesenchymal Stem/Stromal Cell, PBS = Phosphate Buffered Saline, TIMP1 = Tissue inhibitor of Metalloproteinase, MMP = Matrix Metalloproteinase, ADSC CM = ADSC Conditioned Medium, PHBV = Polyhydroxybutyrate-co-Hydroxyvalerate



**Figure 3.** *Harnessing the power of fat for fibrotic scar treatment: as whole adipose tissue in lipofilling, or in loose components such as SVF, ADSC or ADSC conditioned medium. As listed, we propose each form has its own ideal application*

## Future perspectives

As discussed throughout, harnessing the power of fat for fibrotic scar treatment, is an emerging concept in regenerative medicine. Fat can however be used in several fashions: as whole adipose tissue in lipofilling, or in loose components such as SVF, ADSC or even ADSC conditioned medium. In our opinion, each of these forms has its own ideal application in regenerative medicine (Figure 3). The use of whole adipose tissue in lipofilling is optimal when there is a soft tissue defect which needs filling. Besides the ‘volumizing’ effect, scar reduction is a beneficent side effect of this treatment. Though, when extra volume is not a requirement or even a contraindication, the use of SVF offers an excellent alternative. In the setting of fibrotic dermal scars in areas where addition of extra volume is not aesthetically desirable, SVF is a good alternative for whole adipose tissue. Besides for use in dermal fibrotic scars, use of SVF opens the door for other clinical applications. Whole adipose tissue is not fit for use in fibrotic disorders in organs, such as cardiac or liver fibrosis. SVF however, would be a suitable alternative to combat organ fibrosis. SVF has all the requirements to act as a scaffold for repair, since it contains ready-to-use microvasculature, ECM and ADSC to orchestrate the repair process. For example acceleration of wound healing or alteration of early scar formation would be exemplary candidates for use of SVF. Nonetheless, in case of a pre-existing scars, a more rigorous remodeling of the mature scar tissue is necessary. Here, the microvasculature and ECM components of SVF are not a prerequisite. Thus, the application of ADSC would suffice. ADSC could orchestrate the remodeling, for example by immunomodulation or by instruction of the resident tissue cells from a synthetic to a proteolytic or a non-contractile phenotype. Last but not least, ADSC conditioned medium offers the ultimate solution when only instructive (growth) factors are required. In this way, use of allogeneic cells or xenogenic cell culture products can be circumvented, resulting in an off-the-shelf product. ADSC conditioned medium would be ideal for topical application or injection in wounds or developing scars.

## Conclusion

Since Neuber’s first report in 1893, the use of adipose tissue, has gradually developed into an exciting new way to be used in the treatment and prevention of scar tissue. After lipofilling or after application of ADSC, improvement of scar appearance or reduction in scar related pain has been reported in many case reports and clinical studies. Lipofilling and ADSC seem promising to lessen the severity of developing as well as pre-existent fibrotic scarring. A factor which complicates definitive conclusions in the efficacy of lipofilling and ADSC, is the wide variety in experimental design of the studies. Each study uses different outcome measurements, at different time points in pre-existent as well as in developing scarring. Up to date, large randomized controlled clinical trials using lipofilling, ADSC, SVF or ADSC conditioned medium for fibrotic scar treatment, are still lacking. For future randomized controlled clinical trials, we recommend researchers to carefully select their source of stromal cells depending on their goal.

## References

1. Neuber G. Fettransplantation. *Chir Kongr Verhandl Deutsche Gesellschaft für Chir.* . 1893;22:66.
2. Illouz YG. Body contouring by lipolysis: a 5-year experience with over 3000 cases. *Plastic and reconstructive surgery.* Nov 1983;72(5):591-597.
3. Coleman SR. Hand rejuvenation with structural fat grafting. *Plastic and reconstructive surgery.* Dec 2002;110(7):1731-1744; discussion 1745-1737.
4. Cardenas-Camarena L, Arenas-Quintana R, Robles-Cervantes JA. Buttocks fat grafting: 14 years of evolution and experience. *Plastic and reconstructive surgery.* Aug 2011;128(2):545-555.
5. Khouri RK, Eisenmann-Klein M, Cardoso E, et al. Brava and autologous fat transfer is a safe and effective breast augmentation alternative: results of a 6-year, 81-patient, prospective multicenter study. *Plastic and reconstructive surgery.* May 2012;129(5):1173-1187.
6. Coleman SR. Structural fat grafting: more than a permanent filler. *Plastic and reconstructive surgery.* Sep 2006;118(3 Suppl):108s-120s.
7. Rigotti G, Marchi A, Galie M, et al. Clinical treatment of radiotherapy tissue damage by lipoaspirate transplant: a healing process mediated by adipose-derived adult stem cells. *Plastic and reconstructive surgery.* Apr 15 2007;119(5):1409-1422; discussion 1423-1404.
8. Klinger M, Marazzi M, Vigo D, Torre M. Fat injection for cases of severe burn outcomes: a new perspective of scar remodeling and reduction. *Aesthetic plastic surgery.* May 2008;32(3):465-469.
9. Caviggioli F, Maione L, Forcellini D, Klinger F, Klinger M. Autologous fat graft in postmastectomy pain syndrome. *Plastic and reconstructive surgery.* Aug 2011;128(2):349-352.
10. Zuk PA, Zhu M, Mizuno H, et al. Multilineage cells from human adipose tissue: implications for cell-based therapies. *Tissue engineering.* Apr 2001;7(2):211-228.
11. Eto H, Kato H, Suga H, et al. The fate of adipocytes after nonvascularized fat grafting: evidence of early death and replacement of adipocytes. *Plastic and reconstructive surgery.* May 2012;129(5):1081-1092.
12. Kato H, Mineda K, Eto H, et al. Degeneration, regeneration, and cicatrization after fat grafting: dynamic total tissue remodeling during the first 3 months. *Plastic and reconstructive surgery.* Mar 2014;133(3):303e-313e.
13. Dong Z, Peng Z, Chang Q, Lu F. The survival condition and immunoregulatory function of adipose stromal vascular fraction (SVF) in the early stage of nonvascularized adipose transplantation. *PLoS one.* 2013;8(11):e80364.
14. Suga H, Eto H, Aoi N, et al. Adipose tissue remodeling under ischemia: death of adipocytes and activation of stem/progenitor cells. *Plastic and reconstructive surgery.* Dec 2010;126(6):1911-1923.
15. Fisher C, Grahovac TL, Schafer ME, Shippert RD, Marra KG, Rubin JP. Comparison of harvest and processing techniques for fat grafting and adipose stem cell isolation. *Plastic and reconstructive surgery.* Aug 2013;132(2):351-361.
16. Pu LL, Coleman SR, Cui X, Ferguson RE, Jr., Vasconez HC. Autologous fat grafts harvested and refined by the Coleman technique: a comparative study. *Plastic and reconstructive surgery.* Sep 2008;122(3):932-937.
17. Hivernaud V, Lefourn B, Guicheux J, et al. Autologous Fat Grafting in the Breast: Critical Points and Technique Improvements. *Aesthetic plastic surgery.* Aug 2015;39(4):547-561.
18. Tuin AJ, Domerchie PN, Schepers RH, et al. What is the current optimal fat grafting processing technique? A systematic review. *Journal of cranio-maxillo-facial surgery : official publication of the European Association for Cranio-Maxillo-Facial Surgery.* Jan 2016;44(1):45-55.
19. Ibatci A, Caviggioli F, Valeriano V, et al. Comparison of cell number, viability, phenotypic profile, clonogenic, and proliferative potential of adipose-derived stem cell populations between centrifuged and noncentrifuged fat. *Aesthetic plastic surgery.* Oct 2014;38(5):985-993.
20. Eto H, Suga H, Matsumoto D, et al. Characterization of structure and cellular components of aspirated and excised adipose tissue. *Plastic and reconstructive surgery.* Oct 2009;124(4):1087-1097.
21. Carmen GY, Victor SM. Signalling mechanisms regulating lipolysis. *Cellular signalling.* Apr 2006;18(4):401-408.
22. Lin G, Garcia M, Ning H, et al. Defining stem and progenitor cells within adipose tissue. *Stem cells and development.* Dec 2008;17(6):1053-1063.
23. Traktuev DO, Merfeld-Clauss S, Li J, et al. A population of multipotent CD34-positive adipose

stromal cells share pericyte and mesenchymal surface markers, reside in a periendothelial location, and stabilize endothelial networks. *Circulation research*. Jan 4 2008;102(1):77-85.

24. Tang W, Zeve D, Suh JM, et al. White fat progenitor cells reside in the adipose vasculature. *Science* (New York, N.Y.). Oct 24 2008;322(5901):583-586.

25. Crisan M, Yap S, Casteilla L, et al. A perivascular origin for mesenchymal stem cells in multiple human organs. *Cell stem cell*. Sep 11 2008;3(3):301-313.

26. Cawthorn WP, Scheller EL, MacDougald OA. Adipose tissue stem cells meet preadipocyte commitment: going back to the future. *Journal of lipid research*. Feb 2012;53(2):227-246.

27. Balkin DM, Samra S, Steinbacher DM. Immediate fat grafting in primary cleft lip repair. *Journal of plastic, reconstructive & aesthetic surgery : JPRAS*. Dec 2014;67(12):1644-1650.

28. Bollero D, Pozza S, Gangemi EN, et al. Contrast-enhanced ultrasonography evaluation after autologous fat grafting in scar revision. *Il Giornale di chirurgia*. Nov-Dec 2014;35(11-12):266-273.

29. Bruno A, Delli Santi G, Fasciani L, Cimpanari M, Palombo M, Palombo P. Burn scar lipofilling: immunohistochemical and clinical outcomes. *The Journal of craniofacial surgery*. 2013;24(5):1806-1814.

30. Guisantes E, Fontdevila J, Rodriguez G. Autologous fat grafting for correction of unaesthetic scars. *Annals of plastic surgery*. Nov 2012;69(5):550-554.

31. Maione L, Memeo A, Pedretti L, et al. Autologous fat graft as treatment of post short stature surgical correction scars. *Injury*. Dec 2014;45 Suppl 6:S126-132.

32. Mazzola IC, Cantarella G, Mazzola RF. Management of tracheostomy scar by autologous fat transplantation: a minimally invasive new approach. *The Journal of craniofacial surgery*. Jul 2013;24(4):1361-1364.

33. Pallua N, Baroncini A, Alharbi Z, Stromps JP. Improvement of facial scar appearance and microcirculation by autologous lipofilling. *Journal of plastic, reconstructive & aesthetic surgery : JPRAS*. Aug 2014;67(8):1033-1037.

34. Ribuffo D, Atzeni M, Guerra M, et al. Treatment of irradiated expanders: protective lipofilling allows immediate prosthetic breast reconstruction in the setting of postoperative radiotherapy. *Aesthetic plastic surgery*. Dec 2013;37(6):1146-1152.

35. Sardesai MG, Moore CC. Quantitative and qualitative dermal change with microfat grafting of facial scars. *Otolaryngology--head and neck surgery : official journal of American Academy of Otolaryngology-Head and Neck Surgery*. Dec 2007;137(6):868-872.

36. Wang G, Ren Y, Cao W, Yang Y, Li S. Liposculpture and fat grafting for aesthetic correction of the gluteal concave deformity associated with multiple intragluteal injection of penicillin in childhood. *Aesthetic plastic surgery*. Feb 2013;37(1):39-45.

37. Zellner EG, Pfaff MJ, Steinbacher DM. Fat grafting in primary cleft lip repair. *Plastic and reconstructive surgery*. May 2015;135(5):1449-1453.

38. Phulpin B, Gangloff P, Tran N, Bravetti P, Merlin JL, Dolivet G. Rehabilitation of irradiated head and neck tissues by autologous fat transplantation. *Plastic and reconstructive surgery*. Apr 2009;123(4):1187-1197.

39. Negenborn VL, Groen JW, Smit JM, Niessen FB, Mullender MG. The Use of Autologous Fat Grafting for Treatment of Scar Tissue and Scar-Related Conditions: A Systematic Review. *Plastic and reconstructive surgery*. Jan 2016;137(1):31e-43e.

40. Conde-Green A, Marano AA, Lee ES, et al. Fat Grafting and Adipose-Derived Regenerative Cells in Burn Wound Healing and Scarring: A Systematic Review of the Literature. *Plastic and reconstructive surgery*. Jan 2016;137(1):302-312.

41. Huang SH, Wu SH, Chang KP, et al. Alleviation of neuropathic scar pain using autologous fat grafting. *Annals of plastic surgery*. May 2015;74 Suppl 2:S99-104.

42. Maione L, Vinci V, Caviggioli F, et al. Autologous fat graft in postmastectomy pain syndrome following breast conservative surgery and radiotherapy. *Aesthetic plastic surgery*. Jun 2014;38(3):528-532.

43. Panettiere P, Marchetti L, Accorsi D. The serial free fat transfer in irradiated prosthetic breast reconstructions. *Aesthetic plastic surgery*. Sep 2009;33(5):695-700.

44. Ulrich D, Ulrich F, van Doorn L, Hovius S. Lipofilling of perineal and vaginal scars: a new method for improvement of pain after episiotomy and perineal laceration. *Plastic and reconstructive surgery*. Mar 2012;129(3):593e-594e.

45. Klinger M, Caviggioli F, Klinger FM, et al. Autologous fat graft in scar treatment. *The Journal of*

craniofacial surgery. Sep 2013;24(5):1610-1615.

46. Beausang E, Floyd H, Dunn KW, Orton CI, Ferguson MW. A new quantitative scale for clinical scar assessment. *Plastic and reconstructive surgery*. Nov 1998;102(6):1954-1961.
47. Ehrlich HP, Desmouliere A, Diegelmann RF, et al. Morphological and immunochemical differences between keloid and hypertrophic scar. *The American journal of pathology*. Jul 1994;145(1):105-113.
48. van der Veer WM, Bloemen MC, Ulrich MM, et al. Potential cellular and molecular causes of hypertrophic scar formation. *Burns : journal of the International Society for Burn Injuries*. Feb 2009;35(1):15-29.
49. Niessen FB, Spauwen PH, Schalkwijk J, Kon M. On the nature of hypertrophic scars and keloids: a review. *Plastic and reconstructive surgery*. Oct 1999;104(5):1435-1458.
50. Sultan SM, Stern CS, Allen RJ, Jr., et al. Human fat grafting alleviates radiation skin damage in a murine model. *Plastic and reconstructive surgery*. Aug 2011;128(2):363-372.
51. Garza RM, Paik KJ, Chung MT, et al. Studies in fat grafting: Part III. Fat grafting irradiated tissue-improved skin quality and decreased fat graft retention. *Plastic and reconstructive surgery*. Aug 2014;134(2):249-257.
52. Sultan SM, Barr JS, Butala P, et al. Fat grafting accelerates revascularisation and decreases fibrosis following thermal injury. *Journal of plastic, reconstructive & aesthetic surgery : JPRAS*. Feb 2012;65(2):219-227.
53. Huang SH, Wu SH, Chang KP, et al. Autologous fat grafting alleviates burn-induced neuropathic pain in rats. *Plastic and reconstructive surgery*. Jun 2014;133(6):1396-1405.
54. Huang SH, Wu SH, Lee SS, et al. Fat Grafting in Burn Scar Alleviates Neuropathic Pain via Anti-Inflammation Effect in Scar and Spinal Cord. *PloS one*. 2015;10(9):e0137563.
55. Vogel H, Niewisch H, Matioli G. The self renewal probability of hemopoietic stem cells. *Journal of cellular physiology*. Dec 1968;72(3):221-228.
56. Lansdorp PM. Telomere length and proliferation potential of hematopoietic stem cells. *Journal of cell science*. Jan 1995;108 ( Pt 1):1-6.
57. Thomson JA, Itskovitz-Eldor J, Shapiro SS, et al. Embryonic stem cell lines derived from human blastocysts. *Science (New York, N.Y.)*. Nov 6 1998;282(5391):1145-1147.
58. Mizuno H, Tobita M, Uysal AC. Concise review: Adipose-derived stem cells as a novel tool for future regenerative medicine. *Stem cells (Dayton, Ohio)*. May 2012;30(5):804-810.
59. Pittenger MF, Mackay AM, Beck SC, et al. Multilineage potential of adult human mesenchymal stem cells. *Science (New York, N.Y.)*. Apr 2 1999;284(5411):143-147.
60. Bourin P, Bunnell BA, Casteilla L, et al. Stromal cells from the adipose tissue-derived stromal vascular fraction and culture expanded adipose tissue-derived stromal/stem cells: a joint statement of the International Federation for Adipose Therapeutics and Science (IFATS) and the International Society for Cellular Therapy (ISCT). *Cytotherapy*. Jun 2013;15(6):641-648.
61. Yoshimura K, Shigeura T, Matsumoto D, et al. Characterization of freshly isolated and cultured cells derived from the fatty and fluid portions of liposuction aspirates. *Journal of cellular physiology*. Jul 2006;208(1):64-76.
62. Corselli M, Chen CW, Sun B, Yap S, Rubin JP, Peault B. The tunica adventitia of human arteries and veins as a source of mesenchymal stem cells. *Stem cells and development*. May 20 2012;21(8):1299-1308.
63. Zimmerlin L, Donnenberg VS, Pfeifer ME, et al. Stromal vascular progenitors in adult human adipose tissue. *Cytometry. Part A : the journal of the International Society for Analytical Cytology*. Jan 2010;77(1):22-30.
64. Corselli M, Crisan M, Murray IR, et al. Identification of perivascular mesenchymal stromal/stem cells by flow cytometry. *Cytometry. Part A : the journal of the International Society for Analytical Cytology*. Aug 2013;83(8):714-720.
65. Yang D, Wang W, Li L, et al. The relative contribution of paracrine effect versus direct differentiation on adipose-derived stem cell transplantation mediated cardiac repair. *PloS one*. 2013;8(3):e59020.
66. Pawitan JA. Prospect of stem cell conditioned medium in regenerative medicine. *BioMed research international*. 2014;2014:965849.
67. Amos PJ, Kapur SK, Stapor PC, et al. Human adipose-derived stromal cells accelerate diabetic wound healing: impact of cell formulation and delivery. *Tissue engineering. Part A*. May 2010;16(5):1595-1606.



68. Traktuev DO, Prater DN, Merfeld-Clauss S, et al. Robust functional vascular network formation in vivo by cooperation of adipose progenitor and endothelial cells. *Circulation research*. Jun 19 2009;104(12):1410-1420.
69. Rehman J, Traktuev D, Li J, et al. Secretion of angiogenic and antiapoptotic factors by human adipose stromal cells. *Circulation*. Mar 16 2004;109(10):1292-1298.
70. Bauer AL, Jackson TL, Jiang Y. Topography of extracellular matrix mediates vascular morphogenesis and migration speeds in angiogenesis. *PLoS computational biology*. Jul 2009;5(7):e1000445.
71. Agostini T, Spinelli G, Marino G, Perello R. Esthetic restoration in progressive hemifacial atrophy (Romberg disease): structural fat grafting versus local/free flaps. *The Journal of craniofacial surgery*. May 2014;25(3):783-787.
72. Akita S, Yoshimoto H, Ohtsuru A, Hirano A, Yamashita S. Autologous adipose-derived regenerative cells are effective for chronic intractable radiation injuries. *Radiation protection dosimetry*. Oct 2012;151(4):656-660.
73. Tiryaki T, Findikli N, Tiryaki D. Staged stem cell-enriched tissue (SET) injections for soft tissue augmentation in hostile recipient areas: a preliminary report. *Aesthetic plastic surgery*. Dec 2011;35(6):965-971.
74. Peltoniemi HH, Salmi A, Miettinen S, et al. Stem cell enrichment does not warrant a higher graft survival in lipofilling of the breast: a prospective comparative study. *Journal of plastic, reconstructive & aesthetic surgery : JPRAS*. Nov 2013;66(11):1494-1503.
75. Tanikawa DY, Agueno M, Bueno DF, Passos-Bueno MR, Alonso N. Fat grafts supplemented with adipose-derived stromal cells in the rehabilitation of patients with craniofacial microsomia. *Plastic and reconstructive surgery*. Jul 2013;132(1):141-152.
76. Kolle SF, Fischer-Nielsen A, Mathiasen AB, et al. Enrichment of autologous fat grafts with ex-vivo expanded adipose tissue-derived stem cells for graft survival: a randomised placebo-controlled trial. *Lancet (London, England)*. Sep 28 2013;382(9898):1113-1120.
77. Lam MT, Nauta A, Meyer NP, Wu JC, Longaker MT. Effective delivery of stem cells using an extracellular matrix patch results in increased cell survival and proliferation and reduced scarring in skin wound healing. *Tissue engineering. Part A*. Mar 2013;19(5-6):738-747.
78. Lee SH, Lee JH, Cho KH. Effects of Human Adipose-derived Stem Cells on Cutaneous Wound Healing in Nude Mice. *Annals of dermatology*. May 2011;23(2):150-155.
79. Uysal CA, Tobita M, Hyakusoku H, Mizuno H. The Effect of Bone-Marrow-Derived Stem Cells and Adipose-Derived Stem Cells on Wound Contraction and Epithelization. *Advances in wound care*. Jun 1 2014;3(6):405-413.
80. Zonari A, Martins TM, Paula AC, et al. Polyhydroxybutyrate-co-hydroxyvalerate structures loaded with adipose stem cells promote skin healing with reduced scarring. *Acta biomaterialia*. Apr 2015;17:170-181.
81. Yun IS, Jeon YR, Lee WJ, et al. Effect of human adipose derived stem cells on scar formation and remodeling in a pig model: a pilot study. *Dermatologic surgery : official publication for American Society for Dermatologic Surgery [et al.]*. Oct 2012;38(10):1678-1688.
82. Zhang Q, Liu LN, Yong Q, Deng JC, Cao WG. Intralesional injection of adipose-derived stem cells reduces hypertrophic scarring in a rabbit ear model. *Stem cell research & therapy*. 2015;6:145.
83. Castiglione F, Hedlund P, Van der Aa F, et al. Intratunical injection of human adipose tissue-derived stem cells prevents fibrosis and is associated with improved erectile function in a rat model of Peyronie's disease. *European urology*. Mar 2013;63(3):551-560.
84. Klingberg F, Hinz B, White ES. The myofibroblast matrix: implications for tissue repair and fibrosis. *The Journal of pathology*. Jan 2013;229(2):298-309.
85. Spiekman M, Przybyt E, Plantinga JA, Gibbs S, van der Lei B, Harmsen MC. Adipose tissue-derived stromal cells inhibit TGF-beta1-induced differentiation of human dermal fibroblasts and keloid scar-derived fibroblasts in a paracrine fashion. *Plastic and reconstructive surgery*. Oct 2014;134(4):699-712.
86. Verhoekx JS, Mudera V, Walbeehm ET, Hovius SE. Adipose-derived stem cells inhibit the contractile myofibroblast in Dupuytren's disease. *Plastic and reconstructive surgery*. Nov 2013;132(5):1139-1148.

---

---

# VII

## GENERAL DISCUSSION AND FUTURE PERSPECTIVES



1. JOEP C.N. WILLEMSSEN



*General discussion*

Discussing results of this thesis in the background of current literature.

*Future perspectives*

A personal view on times to come.

## General discussion

Volumetric reconstruction by lipofilling on a large scale has been around for over a quarter of a century, with treatment modalities in both aesthetic as well as reconstructive plastic surgery<sup>1-3</sup>. Almost every aspect of the technique, however, is still subject to discussion in current literature<sup>4</sup>. Unfortunately, several surgeons who pioneered in lipofilling made strong claims which lacked sound scientific support. This caused a vigorous debate on the efficacy of lipofilling. Fortunately, in the past decade, basic biological knowledge with regard to lipograft increased, which has resulted in variations of harvesting- processing- and injection techniques<sup>5</sup>. Although knowledge of biological principals behind lipofilling has significantly increased during the past years, many questions remain, such as: ‘what is the optimal technique?’, ‘what is the percentage of graft survival?’, ‘does lipofilling rejuvenate overlying skin?’, ‘what is the role of additives like PRP?’ ‘what is the influence of sex?’ and ‘what is the influence of age and underlying (patho)physiology?’ to mention a few. Increased knowledge of the underlying principles of the procedure may result in optimal – or at least improved – use of lipofilling and could clarify its efficacy in facial rejuvenation. This thesis does not provide answers to all these questions, but delivers a better understanding of the role of lipofilling and the addition of PRP in facial rejuvenation by lipofilling. Also, we present potential pitfalls in future ASC-based human therapies during our journey.

Traditionally, facial rejuvenation is achieved by vertically repositioning the sagged soft tissue, countering the effects of gravity: the facelift<sup>6,7</sup>. With loss of facial volume due to bone and fat atrophy, identified as a major factor in the aging face<sup>8-10</sup>, restoring volume by lipofilling could potentially enhance rejuvenation significantly. Despite uncertainties that surround lipofilling, it could offer a ‘natural’ method of volume restoration of the aging face. Furthermore, it has been suggested that lipofilling improves overlying skin quality, a process that is attributed to the ASC<sup>11</sup>. Permanent fillers like Bioalcamed and silicon were readily used in the ‘80 and ‘90’s, but were abandoned due to a high complication rate<sup>12</sup>. The outcomes of our study (Chapter II) support the fact that lipofilling combined with a lifting procedure significantly increases the overall rejuvenation effect compared to a lifting procedure alone. We corroborate the findings published by other authors<sup>13-15</sup>. It is nowadays commonly accepted that maximal rejuvenation of the aging face can only be achieved by addressing both volume loss as well as lifting sagged soft tissues<sup>8, 15-17</sup>. In other words: by employing a combination therapy.

With mixed reported clinical results<sup>18</sup>, various additions were explored in order to increase fat graft survival and the predictability of graft take<sup>19-22</sup>. Because of promising results reported on the use of platelet rich plasma in chronic wound closure<sup>23</sup> and orthopedics<sup>24</sup>, the first experimental studies revealed an increase in fat graft survival when added to the lipograft<sup>25-26</sup>. Growth factors in the platelet like PDGF and VEGF are known to play a crucial role in tissue inflammatory response<sup>27</sup> and angiogenesis: PDGF promotes wound healing via activation of the local stroma, i.e., connective tissue, while, e.g., VEGF promotes local angiogenesis<sup>28</sup>.<sup>29</sup> Angiogenesis is essential to improve perfusion, i.e., oxygen delivery, but also delivery of immune cells that are essential in adequate wound healing such as alternatively activated macrophages. In a way, the augmentation of lipografts with PRP is thought to reiterate and augment physiological wound healing<sup>24</sup>. Therefore, addition of PRP to the lipograft could increase the rejuvenation effect in facial lipofilling by increasing graft retention and thus gaining volume in a single procedure instead of two or three procedures. Besides the potential effect on surviving lipograft volume, several authors suggested that PRP could also speed up the healing process that would result in a faster recovery time<sup>30-32</sup>. PRP could also enhance

the claimed rejuvenating skin effects of lipofilling, by influencing collagen deposition, turnover and re-modulation<sup>33-35</sup>. In our retrospective study (Chapter III), we found that the addition of PRP indeed boosted the overall aesthetic outcome significantly with a reduction in recovering time after surgery. Combined with a MACS-lift, the rejuvenation effect appeared to be the most profound. Possible explanations of this observation can be found in increased graft retention and improvement of the overlying skin, albeit speculative. No comparable studies exist thus far that have focused on recovery time after facial lipofilling, but additional clinical evidence of reduction of recovery time in facial rejuvenation by PRP was also found in the study of Na et al.<sup>32</sup>.

Preliminary results from our study (Chapter III) inspired us to design of a randomized controlled trial in order to eliminate confounding factors and for the first time investigate the claimed effects of improved skin quality after lipofilling combined with PRP as additive (Chapter IV). Results of our study reproduced the previously reported reduction in recovery time. We found effect, however, of the lipofilling procedure with or without PRP on skin elasticity, a parameter that is commonly accepted in determining skin quality and age<sup>36-40</sup>. This finding raises questions about the claims made by Coleman<sup>1</sup> and many others “that lipofilling is more than a permanent filler”. Results as presented in our study, however, might suffer from our limited sample size. During study design and power calculation (estimated minimal cohort size for a given effect that could result in significant differences), literature did not offer a potential clinical effect size. Because of this, the effect size was a rough estimate derived from fundamental studies and a minimal desired effect (5% gain in elasticity). There could, potentially, be an increase in skin elasticity, but this increase would be lower than 5% compared to a control group.

Thus far, most studies focus on lipofilling in damaged (e.g., radiation, thermal) skin<sup>41-43</sup> in order to reduce excessive scarring, a process that seems to be influenced by ASC in the lipograft. Within the aesthetic domain, the study of Rigotti et al.<sup>38</sup> shows minimal changes in collagen and elastin deposition after facial lipofilling. This finding, however, seems clinically insignificant, as shown by Amirkhani et al.<sup>36</sup>. Recent studies<sup>44,45</sup>, however, show some effect with SVF/ASC boosted lipografts, again underlining the important role of the ASC. Future studies are definitely needed to focus on the relevancy of this effect in a clinical setting, and, if applicable, long term effects to surrounding tissue and for instance the influence of altering physical characteristics of a patient (e.g. aging, BMI-index, diseases). This knowledge seems paramount prior to widespread clinical application. Current literature on the role of SVF/ASC boosted lipografts is reviewed in Chapter VI.

With the clinical relevancy of small volume facial lipofilling still under debate<sup>4,46</sup>, we noted no effect of lipofilling nor lipofilling with PRP on the depth of the nasolabial fold (Chapter IV), despite the fact that previous research with the “Merz Scale” could determine small volume changes (e.g., filler injection)<sup>47</sup>. The absence of changes in nasolabial fold depth probably can be explained by the fact that lipofilling has increased the overall facial volume of the different fat compartments and thereby did not alter the relative differences between facial compartments / zones. It is our opinion that lipofilling can only have an effect on the depth of the nasolabial fold in combination with a facelift. Moreover, in our study, changes in facial volume were minimal because of the limited amounts of lipografts that have been injected. Until now, only one study has clearly demonstrated facial graft retention after facial lipofilling as determined with external 3D photographic reconstruction<sup>46</sup>. In this study, an overall retention of 32% was reported. The range and variation of the reported data in this publication, however, questions its real scientific merit. In addition, the vast number of patients in this study also received some form of facial lifting procedure that most likely also changed the facial volume distribution, and

thereby influenced facial volume that has been attributed to lipofilling. Even though lipograft survival in the face has been documented with MRI imaging<sup>48</sup>, the clinical relevance of facial lipofilling procedures without lifting procedures on facial fold depth remains to be elucidated. Our study raises further questions: is lipofilling really as good as claimed in the past? Apart from the limited level of evidence of Chapter III, one could also state that lipofilling alone is insufficient in facial rejuvenation, since only a vertical lift of soft tissue is able to correct the sagging of the midface and lower facial area (jowls). Increasing facial volume with small volume amounts of fat, as used in our RCT, will not correct the aspect of soft tissue sagging enough. This is in line with the conclusion as drawn in Chapter II: lipofilling will only increase the overall aesthetic outcome of the face when combined with a vertical lift of the sagged soft tissues.

The role of PRP on graft survival in a clinical setting also remains unclear: current literature is inconclusive<sup>49</sup>. Variations in methodology probably create significant bias and obstacles in interpreting and comparing the results<sup>50-52</sup>. The presence of ASC's is most likely an important factor enhancing lipograft retention<sup>20</sup> and improving skin quality<sup>36</sup>, but understanding the role of PRP on ASC is also of paramount importance. As stated in our general introduction, ASCs could attribute to graft survival by several mechanisms: *1: Direct support of adipocytes during the first days after transplantation 2: Inhibit apoptosis pathways of adipocytes 3: Support vascular ingrowth by direct or indirect effects on endothelial cells 4: Differentiate into adipocytes.*

It has been shown that the concentration of produced PRP is rather variable, depending on the methods of creation and donor platelet count<sup>52</sup>. Fundamental studies in vitro have shown a clear concentration dependent effect of PRP on various cell-lines<sup>53-56</sup>. With findings, as presented in Chapter V, we unveiled the importance of PRP concentration in the lipograft: a higher concentration of PRP is not always better. Although high concentrations of PRP proved to be to most powerful mitogen for ASC expansion, it inadvertently seems to change the genotype ASC into a fibroblast like form: apparently, gene expression of ECM related genes are decreased and pro-angiogenic gene expression are also depressed when exposed to high PRP concentrations in the culture medium. Elaborating on this finding, ASC altered genotype translated into its secretome: with inhibition of endothelial cell sprouting capabilities (Chapter V). Both of these changes negatively influence the outcome of facial lipofilling.

The results from our study (Chapter V) will give us hints in how we have to use PRP in lipofilling and ASC cell culture. Care must be taken for the right dose of PRP: its concentration, as well as the end concentration within the lipograft or cell culture, has significant influence on graft / cell survival and differentiation. This concentration aspect may explain the variety of results observed thus far in "PRP-lipofilling literature". This conclusion was made after we already had designed and started our RCT (Chapter IV). Besides reducing recovery time, absence of PRP effects on skin elasticity and lipograft volume in this study could partially be explained by findings as described in Chapter V, and questions the value of its use as described in our RCT. In our opinion, adding PRP to the lipograft can only work synergetic within a very small therapeutic window that cannot be achieved with the current available disposable PRP kits. Moreover, transdermal delivery of PRP into the lipofilled tissue planes, as in our RCT, is also probably not precise enough. Future 'tailor made' lipografts, with known ASC-adipocyte composition, might leave a role for PRP addition.

Besides PRP being an interesting additive to lipofilling in a clinical setting because of faster recovery time, PRP could also play an import role in ASC-therapies. The study of Kolle et al.

clearly demonstrated that ASCs exert a dose-dependent influence in the lipograft<sup>20, 57</sup>, and also showed that ASCs might expand *in vivo* in lipografts<sup>57</sup>. Expansion of ASC's *in vitro* can only be achieved by means of adding growth factors to the culture medium. In an experimental setting, most studies use bovine serum components. Interestingly, many positive effects attributed to ASC (Chapter VI) are based on the use of culture media that are supplemented with bovine serum, whereas ASCs cultured on human serum (in our case PRP) differ significantly from bovine cultures as demonstrated in Chapter V. Results of our study are supported by the Bieback et al.<sup>58</sup> and Blande et al.<sup>59</sup>. Future ASC's based clinical therapies preferably should use human platelet derivatives in order to minimize inflammatory responses towards bovine proteins and the potential of animal pathogen transmission that may be harmful to humans (e.g. Creutzfeldt-Jakob disease)<sup>59</sup>. Despite the promising results observed in anti-fibrotic ASC therapies in animal and limited human studies (Chapter VI), reliable achievement of these effects in large clinical series is only possible with a better understanding of platelet lysate based ASC cultures and the effects of the lysate concentrate.

## Future perspectives

Lipofilling and ASC therapies seem to harness the future of medicine: with lipofilling reconstruction and / or rejuvenation can be achieved on a cellular level. We probably stand at the beginning of a spectacular journey that may take several decades but finally will result in effective human stem cell therapies at its end. Evolutionary, this could be the next step for human species: fast (scarring) wound healing could be regulated by lipofilling and ASC therapies. In theory, this could result in scarless healing without functional loss, a healing very similar to that what occurs in early fetal stages.

We believe that future stem cell therapies will offer scarless fetal wound healing, an ability that has been lost in mature mankind wound healing. PRP, or platelet lysates, will definitely also have a role in these perspectives, probably for *in vitro* for cell expansion and potentially clinically if we gain further understanding of its working and interactions. However, it is currently unlikely that we can control *in vivo* PRP concentrations when used as an additive to the lipograft in the near future.

Currently, the scientific evidence for the “clinical observed” rejuvenation effects procedures with lipofilling needs to be further substantiated. No consensus exists about most aspects of the lipofilling procedure itself, and therefore no universal standard method has yet been established. With only case reports, claims like skin improvement have been accepted and are nowadays regularly used in patient consultations. Although the volume effect of lipofilling is established and definitely needed in optimal facial rejuvenation procedures, it is surprising that terms as skin improvement are still used so frequently in clinical consultation without sufficient scientific evidence. Because of spectacular clinical results observed in the early '90, extensive clinical application has spread over the world without real proof of the underlying idea or mechanism. Several factors may count for this course: the commercial circuit demanding speed and widespread application of new spectacular therapies and the spectacular results as observed in the early nineties. In order to get a better and sound scientific base for widespread clinical application of lipofilling and ASC related therapies, we must change our mentality towards ‘look before leaping’. Further elaboration with the research field of fundamental biology would be therefore most advantageous. Basic knowledge of what happens on a cellular level will finally lead to evidence-based clinical therapies. Furthermore, the gap between *in vitro* research and the clinician should be bridged, resulting in fundamental research that focuses on relevant clinical topics. As such, this thesis is an example of such a valuable collaboration.

In addition to a lack of basic understanding and science, there is a shortage of reproducible controlled clinical trials in aesthetic surgery. Literature thus far mainly consists of small, non-blinded non-randomized studies, often with various methodology. Lipofilling also is a perfect example for this aspect: variations in the technique itself have resulted in limited scientific evidence. The formation of an international scientific committee or consortium that dictates methodical guidelines for lipofilling could reduce the number of variables involved, and may subsequently result in reliable data for meta-analysis. Only well designed randomized controlled trials, with minimal variations in methodology, can answer the questions stated in the first paragraph of the general discussion in this thesis.

Publishing negative results, i.e., results that fail to confirm the hypothesis after well controlled clinical trials, should also be published and not be pushed away. As in this thesis, for example, the observation of the lack of increase in skin elasticity in our RCT (Chapter IV) has shown to be an unwelcome message for reviewers, probably because this observation is “not wanted to be found for whatever reason”. In my opinion, any result from an RCT should be of value, since it could form reference and baseline during designing and power calculations of future RCTs within the subject. Also, publication of RCT with a faulty design could be of great educational value when its fault is revealed and discussed.

Therefore, in order to eliminate any form of conflict of interest by reviewers and journals in publishing negative results, submission of the study in an earlier phase should be done. For example, with respect to an RCT, before the inclusion starts, submission of all the details, purpose and methods to journal should be undertaken to let them judge and decide whether or not the methodology is sound, and if the topic is within the journals’ scope. If accepted, the journal should be committed in publishing the results and whether they are to be expected (positive) or not (negative). Also, a critical review by independent reviewers of a suggested study’s methodology could result in better study quality. Fortunately, the rise of many open access journal greatly expands the reach of ‘negative result studies’ compared to recent history. In my opinion, open access journals are the way forward: data must be available for everyone at every time. Sharing could lead to increased efficiency, potentially lower costs and collaboration/synergy within research in general.

The future looks promising, but also is challenging and demanding: let’s learn from the past and join all our forces to finally discover the clues for scarless healing and rejuvenation.

JW



## References

1. Gutowski KA, ASPS Fat Graft Task Force. Current applications and safety of autologous fat grafts: A report of the ASPS fat graft task force. *Plast Reconstr Surg*. 2009;124:272-280.
2. Simonacci F, Bertozzi N, Grieco MP, Grignaffini E, Raposio E. Procedure, applications, and outcomes of autologous fat grafting. *Ann Med Surg (Lond)*. 2017;20:49-60.
3. Hsu VM, Stransky CA, Bucky LP, Percec I. Fat grafting's past, present, and future: Why adipose tissue is emerging as a critical link to the advancement of regenerative medicine. *Aesthet Surg J*. 2012;32:892-899.
4. Sinno S, Wilson S, Brownstone N, Levine SM. Current thoughts on fat grafting: Using the evidence to determine fact or fiction. *Plast Reconstr Surg*. 2016;137:818-824.
5. Tuin AJ, Domerchie PN, Schepers RH et al. What is the current optimal fat grafting processing technique? A systematic review. *J Craniomaxillofac Surg*. 2016;44:45-55.
6. Tonnard P, Verpaele A, Monstrey S et al. Minimal access cranial suspension lift: A modified S-lift. 2002;109:2074-2086.
7. DeFatta RJ, Williams EF,3rd. Evolution of midface rejuvenation. *Arch Facial Plast Surg*. 2009;11:6-12.
8. Cotofana S, Fratila AA, Schenck TL, Redka-Swoboda W, Zilinsky I, Pavicic T. The anatomy of the aging face: A review. *Facial Plast Surg*. 2016;32:253-260.
9. Donofrio LM. Techniques in facial fat grafting. 2008;28:681-687.
10. Fitzgerald R, Graivier MH, Kane M et al. Update on facial aging. *Aesthetic surgery journal / the American Society for Aesthetic Plastic surgery*. 2010;30 Suppl:11S-24S.
11. Coleman SR. Structural fat grafting: More than a permanent filler. *Plastic and reconstructive surgery*. 2006;118:108S-120S.
12. Coleman SR. Facial recontouring with lipostructure. 1997;24:347-367.
13. Pontius AT, Williams EF,3rd. The evolution of midface rejuvenation: Combining the midface-lift and fat transfer. *Arch Facial Plast Surg*. 2006;8:300-5.
14. Ramirez OM. Full face rejuvenation in three dimensions: A "face-lifting" for the new millennium. *Aesthetic Plast Surg*. 2001;25:152-164.
15. Pallua N, Wolter T. The lipo-facelift: Merging the face-lift and liposculpture: Eight years experience and a preliminary observational study. *Aesthetic Plast Surg*. 2013;37:1107-1113.
16. Guerrero Santos J. Evolution of technique: Face and neck lifting and fat injections. *Clinics in plastic surgery*. 2008;35:663-76, viii.
17. DeFatta RJ, Williams EF,3rd. Fat transfer in conjunction with facial rejuvenation procedures. 2008;16:383-90, v.
18. Kaufman MR, Miller TA, Huang C et al. Autologous fat transfer for facial recontouring: Is there science behind the art?. *Plastic and reconstructive surgery*. 2007;119:2287-96.
19. Gir P, Brown SA, Oni G, Kashefi N, Mojallal A, Rohrich RJ. Fat grafting: Evidence-based review on autologous fat harvesting, processing, reinjection, and storage. *Plast Reconstr Surg*. 2012;130:249-258.
20. Trojahn Kolle SF, Oliveri RS, Glovinski PV, Elberg JJ, Fischer-Nielsen A, Drzewiecki KT. Importance of mesenchymal stem cells in autologous fat grafting: A systematic review of existing studies. *Journal of plastic surgery and hand surgery*. 2012;46:59-68.
21. Hong SJ, Lee JH, Hong SM, Park CH. Enhancing the viability of fat grafts using new transfer medium containing insulin and beta-fibroblast growth factor in autologous fat transplantation. 2009.
22. Martinez-Zapata MJ, Marti-Carvajal A, Sola I et al. Efficacy and safety of the use of autologous plasma rich in platelets for tissue regeneration: A systematic review. *Transfusion*. 2009;49:44-56.
23. Henderson JL, Cupp CL, Ross EV et al. The effects of autologous platelet gel on wound healing. *Ear, nose, & throat journal*. 2003;82:598-602.
24. Alsousou J, Thompson M, Hulley P, Noble A, Willett K. The biology of platelet-rich plasma and its application in trauma and orthopaedic surgery: A review of the literature. *J Bone Joint Surg Br*. 2009;91:987-996.
25. Oh DS, Cheon YW, Jeon YR, Lew DH. Activated platelet-rich plasma improves fat graft survival in nude mice: A pilot study. *Dermatologic surgery : official publication for American Society for Dermatologic Surgery [et al ]*. 2011;37:619-25.
26. Pires Fraga MF, Nishio RT, Ishikawa RS, Perin LF, Jr AH, Malheiros CA. Increased survival of free fat grafts with platelet-rich plasma in rabbits. *J Plast Reconstr Aesthet Surg*. 2010.

27. Rudkin GH, Miller TA. Growth factors in surgery. *Plastic and reconstructive surgery*. 1996;97:469-76.
28. Gehmert S, Hidayat M, Sultan M et al. Angiogenesis: The role of PDGF-BB on adipose-tissue derived stem cells (ASCs). *Clinical hemorheology and microcirculation*. 2011;48:5-13.
29. Mammoto T, Jiang A, Jiang E, Mammoto A. Platelet rich plasma extract promotes angiogenesis through the angiopoietin1-Tie2 pathway. *Microvasc Res*. 2013;89:15-24.
30. Lee JW, Kim BJ, Kim MN, Mun SK. The efficacy of autologous platelet rich plasma combined with ablative carbon dioxide fractional resurfacing for acne scars: A simultaneous split-face trial. *Dermatologic surgery : official publication for American Society for Dermatologic Surgery [et al.]*. 2011;37:931-8.
31. Jo CH, Kim JE, Yoon KS et al. Does platelet-rich plasma accelerate recovery after rotator cuff repair? A prospective cohort study. *The American journal of sports medicine*. 2011;39:2082-90.
32. Na JI, Choi JW, Choi HR et al. Rapid healing and reduced erythema after ablative fractional carbon dioxide laser resurfacing combined with the application of autologous platelet-rich plasma. *Dermatologic surgery : official publication for American Society for Dermatologic Surgery [et al.]*. 2011;37:463-8.
33. Cameli N, Mariano M, Cordone I, Abril E, Masi S, Foddai ML. Autologous pure platelet-rich plasma dermal injections for facial skin rejuvenation: Clinical, instrumental, and flow cytometry assessment. *Dermatol Surg*. 2017;43:826-835.
34. Cho JM, Lee YH, Baek RM, Lee SW. Effect of platelet-rich plasma on ultraviolet b-induced skin wrinkles in nude mice. *J Plast Reconstr Aesthet Surg*. 2010.
35. Cho JW, Kim SA, Lee KS. Platelet-rich plasma induces increased expression of G1 cell cycle regulators, type I collagen, and matrix metalloproteinase-1 in human skin fibroblasts. *Int J Mol Med*. 2012;29:32-36.
36. Amirkhani MA, Shoaee-Hassani A, Soleimani M, Hejazi S, Ghalichi L, Nilforoushzadeh MA. Rejuvenation of facial skin and improvement in the dermal architecture by transplantation of autologous stromal vascular fraction: A clinical study. *Bioimpacts*. 2016;6:149-154.
37. Colman CE, Steele JR, McGhee DE. Effect of aging on breast skin thickness and elasticity: Implications for breast support. *Skin Res Technol*. 2016.
38. Charles-de-Sa L, Gontijo-de-Amorim NF, Maeda Takiya C et al. Antiaging treatment of the facial skin by fat graft and adipose-derived stem cells. *Plast Reconstr Surg*. 2015;135:999-1009.
39. Ezure T, Amano S. Influence of subcutaneous adipose tissue mass on dermal elasticity and sagging severity in lower cheek. *Skin Res Technol*. 2010;16:332-338.
40. Draaijers LJ, Botman YA, Tempelman FR, Kreis RW, Middelkoop E, van Zuijlen PP. Skin elasticity meter or subjective evaluation in scars: A reliability assessment. *Burns*. 2004;30:109-14.
41. Rigotti G, Marchi A, Galie M et al. Clinical treatment of radiotherapy tissue damage by lipoaspirate transplant: A healing process mediated by adipose-derived adult stem cells. *Plastic and reconstructive surgery*. 2007;119:1409-22; discussion 1423-4.
42. Jaspers ME, Brouwer KM, van Trier AJ, Groot ML, Middelkoop E, van Zuijlen PP. Effectiveness of autologous fat grafting in adherent scars: Results obtained by a comprehensive scar evaluation protocol. *Plast Reconstr Surg*. 2016.
43. Klinger M, Marazzi M, Vigo D, Torre M. Fat injection for cases of severe burn outcomes: A new perspective of scar remodeling and reduction. *Aesthetic plastic surgery*. 2008;32:465-9.
44. Rigotti G, Charles-de-Sa L, Gontijo-de-Amorim NF et al. Expanded stem cells, stromal-vascular fraction, and platelet-rich plasma enriched fat: Comparing results of different facial rejuvenation approaches in a clinical trial. *Aesthet Surg J*. 2016;36:261-270.
45. Li J, Gao J, Cha P et al. Supplementing fat grafts with adipose stromal cells for cosmetic facial contouring. *Dermatol Surg*. 2013;39:449-456.
46. Meier JD, Glasgold RA, Glasgold MJ. Autologous fat grafting: Long-term evidence of its efficacy in midfacial rejuvenation. *Arch Facial Plast Surg*. 2009;11:24-28.
47. Cohen SR, Berner CF, Busso M et al. ArteFill: A long-lasting injectable wrinkle filler material--summary of the U.S. food and drug administration trials and a progress report on 4- to 5-year outcomes. *Plast Reconstr Surg*. 2006;118:645-76S.
48. Swanson E. Malar augmentation assessed by magnetic resonance imaging in patients after face lift and fat injection. *Plastic and reconstructive surgery*. 2011;127:2057-65.
49. Liao HT, Marra KG, Rubin JP. Application of platelet-rich plasma and platelet-rich fibrin in fat grafting:

Basic science and literature review. *Tissue Eng Part B Rev.* 2014;20:267-276.

50. Woodell-May JE, Ridderman DN, Swift MJ, Higgins J. Producing accurate platelet counts for platelet rich plasma: Validation of a hematology analyzer and preparation techniques for counting. *J Craniofac Surg.* 2005;16:749-56; discussion 757-9.

51. Sommeling CE, Heyneman A, Hoeksema H, Verbelen J, Stillaert FB, Monstrey S. The use of platelet-rich plasma in plastic surgery: A systematic review. *J Plast Reconstr Aesthet Surg.* 2013;66:301-311.

52. Mazzocca AD, McCarthy MB, Chowaniec DM et al. Platelet-rich plasma differs according to preparation method and human variability. *The Journal of bone and joint surgery American volume.* 2012;94:308-16.

53. Creeper F, Lichanska AM, Marshall RI, Seymour GJ, Ivanovski S. The effect of platelet-rich plasma on osteoblast and periodontal ligament cell migration, proliferation and differentiation. *Journal of periodontal research.* 2009;44:258-65.

54. Graziani F, Ivanovski S, Cei S, Ducci F, Tonetti M, Gabriele M. The in vitro effect of different PRP concentrations on osteoblasts and fibroblasts. *Clinical oral implants research.* 2006;17:212-9.

55. Weibrich G, Hansen T, Kleis W, Buch R, Hitzler WE. Effect of platelet concentration in platelet-rich plasma on peri-implant bone regeneration. *Bone.* 2004;34:665-71.

56. Yamaguchi R, Terashima H, Yoneyama S, Tadano S, Ohkohchi N. Effects of platelet-rich plasma on intestinal anastomotic healing in rats: PRP concentration is a key factor. *The Journal of surgical research.* 2010.

57. Kolle SF, Fischer-Nielsen A, Mathiasen AB et al. Enrichment of autologous fat grafts with ex-vivo expanded adipose tissue-derived stem cells for graft survival: A randomised placebo-controlled trial. *Lancet.* 2013;382:1113-1120.

58. Bieback K. Platelet lysate as replacement for fetal bovine serum in mesenchymal stromal cell cultures. *Transfus Med Hemother.* 2013;40:326-335.

59. Blande IS, Bassaneze V, Lavini-Ramos C et al. Adipose tissue mesenchymal stem cell expansion in animal serum-free medium supplemented with autologous human platelet lysate. *Transfusion.* 2009;49:2680-2685.

---

---

# VIII

## SUMMARY - SAMENVATTING



1. JOEP C.N. WILLEMSSEN

## Summary

New insights in facial aging made it apparent that not only sagging/ptosis but also facial volume loss is a major factor of this process. Classic facial rejuvenating procedures that only lift or reposition tissue in a vertical vector did not correct for facial volume loss. Permanent fillers, like Bioalcamed and silicone were readily used in the '80 and '90's but were subsequently abandoned due to the high complication rate. Since the (re-)introduction of lipofilling it appeared that this procedure is a well-tolerated natural alternative to correct for volume loss due to facial aging. Furthermore, with ongoing experience and research it seems that Adipose Stem Cells (ASC) being present in the lipograft have regenerative capabilities on surrounding tissue like overlying skin. The success and extent of the effect of lipofilling, however, is plagued by a vast number of variables, like the technique of harvesting, the fat processing and injection of the lipograft; factors that all influence the lipograft viability and the ASC (Chapter I: General introduction). Platelet Rich Plasma (PRP) has been suggested to increase the lipograft viability and retention. Moreover, PRP could also increase wound healing resulting in a faster recovery. With our studies (Chapters II-IV) we have attempted to investigate and clarify the role of lipofilling and lipofilling with the additional use of PRP in facial rejuvenation with regard to the aesthetic outcome, possible regenerative skin effects and recovery time. Also, we have tried to unravel the effects of PRP on the ASC itself (Chapter V). Expanding knowledge and understanding of the lipograft as well as the role of additives like PRP, could result in optimization current and future clinical techniques to achieve far better lipograft survival and/or regenerative capability.

Utilizing new insights on the importance of volume loss in the aging face, the addition of lipofilling to facelift procedures could increase the overall facial rejuvenation effect. In Chapter II we have demonstrated that MACS-lifting with lipofilling indeed significantly boosts aesthetic outcome as compared to MACS-lifting without lipofilling. The results, as presented in this chapter, support the hypothesis that restoring facial volume is a key factor in obtaining significant better facial rejuvenation. Besides volume, the potential rejuvenating effect on overlying skin could attribute to the overall increase in outcome.

Thus far, PRP is already frequently used as an additive in lipofilling procedures in order to increase the overall outcome and to reduce recovery time. However, limited supporting evidence is found in literature. Therefore, we felt that the time was there to validate these claims. In Chapter III, we retrospectively analyzed a total of 82 patients that either had a MACS-lift with lipofilling +/- PRP, or lipofilling alone +/- PRP. Patient reported recovery time, defined by the number of days returning to work or social activities, was significantly lower in patients that received lipofilling with PRP as compared to patients that had only lipofilling without PRP. The addition of PRP had no significant effect on recovery in the series of patients that had a MACS-lift procedure with lipofilling alone. In this Chapter III, we also demonstrate that PRP resulted in superior aesthetic outcome in both lipofilling and MACS-lift with lipofilling procedures.

The results as presented Chapter III were thus inspiring, that further investigation was warranted on the potential factors that could be attributed to the superior result evoked by adding PRP. With local skin effects (elasticity changes that correlate to age) and increased graft take as the most likely candidates, we initiated a double-blinded randomized controlled trial (Chapter IV). With this randomized study, we conclusively demonstrated that the addition of PRP to the lipofilling procedure had no significant effect on both skin elasticity and volume changes of the nasolabial fold area. Also, the lipofilling procedure without PRP did not improve skin elasticity. However, regression analysis of skin elasticity as a function of age did show a reversal from negative to positive. This finding could indicate that some rejuvenation effect of

the procedures on the skin does occur but we were not able to find a significant effect due to the small study population size (only 25 patients completed the twelve-month follow-up). Nevertheless, when focusing on patient recovery, we again demonstrated a significant drop in the number of days before returning to work / social activities.

The ASC in the lipograft seem to be of crucial importance for the potential regenerative effects of the lipofilling procedure as well as of the survival of the injected lipograft. With this in mind, PRP probably will have effect on the ASC when added to the lipograft: further research on this item is therefore crucial and worth doing. In Chapter V, a fundamental study, we demonstrate that PRP has a concentration depended effect on ASC in vitro: on proliferation, gene expression and secretome. Our results clearly demonstrated an optimal window for the PRP concentration, with to low and to high concentrations resulting in potential negative effect. ASC exposed to high PRP concentrations show a high rate of proliferation, but they seem to change into a fibroblast-like phenotype. The most striking support for this latter claim is presented in the endothelial sprouting assay as presented in this chapter: conditioned medium (medium that contained the secretome produced by the cells) collected from ASC exposed to high PRP concentrations blocked all sprouting. However, direct addition of high PRP concentrations to the sprouting assay resulted in a higher number, and more stable loop formation. All these results as presented in Chapter V, thus clearly demonstrate that PRP has a certain therapeutic window for getting optimal beneficiary effects. It seems questionable if this therapeutic window can be achieved in a clinical setting with the PRP capture devices we have used in our RCT (Chapter IV) as PRP capture devices did not deliver a constant number of platelets. Therefore, based upon our studies, we think that the variable results of PRP as presented in current literature, especially when added to the lipograft, could be due to failing in reaching the therapeutic window: it is a concentration depended effect.

Lipofilling or the use of ASC seems to improve scar appearance and/or reduce in scar related pain, as has been reported in many case reports and clinical studies. Therefore, in Chapter VI of this thesis we have reviewed current literature on the regenerative effects of the lipograft and the ASC. This thorough review demonstrated that the use of lipofilling and ASC seem to lessen the severity of ongoing scarring as well as pre-existent fibrotic scarring. Definite conclusions could not be made because of the great variety in experimental study design in all these publications. Each study did use different outcome measurements at different time points in pre-existent as well as in developing scars. Unfortunately, up to date, large randomized controlled clinical trials using lipofilling, ASC, Stromal Vascular Fraction or ASC conditioned medium for fibrotic scar treatment, are still lacking. Therefore, we strongly advice to initiate such clinical studies in a randomized controlled way and recommend to select the optimal source of stromal cells, depending on the indication for use.

## Samenvatting

Nieuwe inzichten over gezichtsveroudering heeft duidelijk gemaakt dat niet alleen verzakking (ptosis vaak in medische termen genoemd), maar ook volume verlies een belangrijke rol speelt in dit proces. Klassieke gezichtsverjongingsprocedures, zoals de klassieke facelift, liften alleen de gezakte weefsels (vaak alleen in verticale richting) maar corrigeren niet voor het volume verlies van het gelaat.

In de jaren "80 en "90 werden permanente fillers, zoals Bioalcomed en siliconen, veelvuldig gebruikt om dit volumeverlies te corrigeren. Echter na een tweetal decennia werd het gebruik ervan ook weer verlaten in verband met de ernstige infectieuze complicaties die permanente fillers met zich mee bleken te brengen. Sinds de grootschalige (her) introductie van lipofilling in de laat jaren "90 is gebleken dat deze procedure een veel beter en goed natuurlijk alternatief is om volumeverlies in het gezicht ten gevolge van gezichtsveroudering te corrigeren. Nieuwe kennis, opgedaan uit klinische ervaring en wetenschappelijk onderzoek heeft bovendien aangetoond dat Adipose Stem Cells (ASC) in het getransplanteerde vet ("de lipograaft") bovendien ook nog de verouderede weefsels lijkt te herstellen (zogenaamd regeneratief vermogen).

Het werkelijke effect van lipofilling is echter moeilijk vast te stellen en te bepalen doordat er een heel groot aantal variabelen in de methodiek van lipofilling zelf zit: de manier waarop vet geogst wordt, hoe vet verwerkt wordt na het oogsten, en de manier waarop het wordt ingespoten. Al deze factoren zijn van invloed op de overleving van het ingespoten vet (Hoofdstuk I: Algemene inleiding). Plaatjes rijk plasma (Platelet Rich Plasma = PRP) lijkt de levensvatbaarheid en daarmee de overleving van de ingespoten vetcellen te verbeteren. Bovendien kan PRP ook de wondgenezing positief beïnvloeden en daardoor mogelijk tot sneller herstel leiden.

Met onze studies (Hoofdstukken II-IV) hebben we geprobeerd de rol van lipofilling en het additioneel gebruik van PRP met lipofilling op gezichtsverjonging te onderzoeken en te verduidelijken. Specifiek werd er gekeken naar de effecten op de esthetische uitkomst, de mogelijke regeneratieve effecten op de huid en de hersteltijd na de operatie. We hebben ook geprobeerd de effecten van PRP op het ASC zelf te ontrafelen (hoofdstuk V). Uitbreiding van de kennis en inzichten op het getransplanteerde vet samen met de rol van additieven zoals PRP zouden kunnen resulteren in verdere optimalisatie van lipofilling. Het ultieme doel is het optimaliseren en maximaliseren van de overlevingskans en/of regeneratief vermogen van het ingespoten vet (de lipograaft).

Voortbordurend op de nieuwe inzichten over het belang van volumeverlies bij gezichtsveroudering, zou de toevoeging van lipofilling aan faceliftprocedures het effect op gezichtsverjonging enorm moeten kunnen vergroten. In Hoofdstuk II hebben we aangetoond dat MACS-lifting (Minimal Access Cranial Suspension lift) met lipofilling inderdaad de esthetische resultaten significant verbetert ten opzichte van MACS-lifting zonder lipofilling. De resultaten, zoals gepresenteerd in dit hoofdstuk, ondersteunen de hypothese dat het herstel van gezichtsvolume een sleutelfactor is voor optimale en betere gezichtsverjonging. Naast het volume effect, zou er ook een verjongend effect van lipofilling op de huid kunnen zijn die bijdraagt aan de gezichtsverjonging.

Het gebruik van PRP als toevoeging bij lipofilling-procedures met als doel het algehele resultaat te vergroten en de hersteltijd te verkorten is al eens beschreven in de literatuur. Echter is het wetenschappelijk bewijs ervan is erg summier. Gezien de vele claims van dit

effect met beperkt bewijs maakte dat we het tijd vonden om deze beweringen eens goed wetenschappelijk te testen en te valideren. In hoofdstuk III analyseerden we daarom in een retrospectieve studie in totaal 82 patiënten die een MACS-lift met lipofilling +/- PRP, of lipofilling alleen +/- PRP hadden ondergaan. De door de patiënt gerapporteerde hersteltijd, gedefinieerd als het aantal dagen tot hervatting van het werk of sociale activiteiten, was significant lager bij patiënten die lipofilling hadden gehad met toevoeging van PRP. De toevoeging van PRP had echter geen significant effect op het herstel in de groep patiënten met een MACS-liftprocedure gecombineerd met lipofilling. In hoofdstuk III laten we ook zien dat PRP resulteerde in een superieure esthetische uitkomst bij zowel lipofilling als MACS-lift met lipofilling-procedures.

De resultaten, zoals gepresenteerd in hoofdstuk III, waren dus inspirerend. Dit rechtvaardigde onderzoek naar de achterliggende factoren die ten grondslag liggen aan de betere esthetische uitkomsten met ook kortere hersteltijd na de operatie. De potentiële lokale huideffecten (elasticiteitsveranderingen die negatief correleren met de leeftijd) en een beter behoud van het ingespoten getransplanteerde vet volume door PRP zouden hierin bepalend kunnen zijn. Met deze kennis, werd een dubbelblind gerandomiseerde gecontroleerde studie gestart (Hoofdstuk IV). Met deze gerandomiseerde studie hebben we overtuigend aangetoond dat de toevoeging van PRP aan de lipofilling-procedure helaas geen significant effect had op zowel de huidelasticiteit als de volumeveranderingen van het nasolabiale plooi gebied. Ook verbeterde de lipofilling-procedure zonder PRP de elasticiteit van de huid niet. Echter, regressieanalyse met de huidelasticiteit als functie van leeftijd toonde wel een omkering van negatief naar positief aan. Deze bevinding kan erop duiden dat er wel enig verjongingseffect van de procedure op de huid optreedt. Het is aannemelijk dat we geen significant effect konden vinden vanwege de kleine omvang van de onderzoekspopulatie (slechts 25 patiënten voltooiden de follow-up van twaalf maanden). Net zoals bij de retrospectieve analyse in hoofdstuk III, toonden we opnieuw een significante daling aan van het aantal dagen die patiënten nodig hadden om hersteld weer naar werk/sociale activiteiten terug te keren door de toevoeging van PRP.

De adipose stamcellen in het ingespoten getransplanteerde vet (de lipograft) lijken van cruciaal belang te zijn voor de potentiële regeneratieve effecten van de lipofilling-procedure en voor het overleven van het geïnjecteerde vet. Met dit in gedachten, is de hypothese dat PRP betere uitkomsten van het ingespoten vet veroorzaakt door de aanwezigheid van ASC in het geogste en ingespoten vet: verder onderzoek naar dit effect is daarom van groot belang. Hoofdstuk V, een fundamenteel onderzoek, laat zien dat PRP een concentratie-afhankelijk effect heeft op proliferatie, genexpressie en secretoom van ASC in vitro. Onze resultaten toonden een duidelijk optimale PRP-concentratie aan voor het beste effect; lage en te hoge concentraties resulterende in duidelijk verminderde werking. ASC blootgesteld aan hoge PRP-concentraties vertonen een hoge mate van proliferatie, maar lijken te veranderen in een fibroblast-achtig fenotype cellen. De meest opvallende ondersteuning voor de concentratie afhankelijke effecten zijn aangetoond met de endotheliale ontspruitings essay in dit hoofdstuk: geconditioneerd medium (medium dat het door de cellen geproduceerde secretoom bevatte) verzameld uit ASC blootgesteld aan hoge PRP-concentraties blokkeerde de vorming van nieuwe bloedvaatjes. Echter toonde directe toevoeging van hoge PRP-concentraties aan het endotheliale ontspruitingsessay wel een hoger aantal en stabielere vaatnetwerk aan. Hoge PRP-concentraties beïnvloeden dus het gedrag van de ASC negatief als we kijken naar vaatvorming, maar heeft op zichzelf wel een positief effect op de vaatvormende cellen. De resultaten, zoals gepresenteerd in hoofdstuk V, tonen dus duidelijk aan dat PRP een bepaald therapeutisch



venster heeft voor het verkrijgen van optimale gunstige effecten. Het lijkt twijfelachtig of dit therapeutische venster in een klinische omgeving wel makkelijk bereikt kan worden met de PRP-capture-apparaten die we in onze RCT hebben gebruikt (Hoofdstuk IV). Dit omdat PRP-capture-apparaten niet een constant aantal bloedplaatjes afleverden. Daarom denken we dat, op basis van onze studies, de variabele resultaten van PRP, zoals gepresenteerd in de huidige literatuur, te verklaren kunnen zijn door het beperkte therapeutische venster: het is een duidelijk concentratie afhankelijk effect.

In de huidige literatuur bestaan er meerdere case-reports en enige klinische studies die hebben aangetoond dat lipofilling en injecties met geïsoleerde ASC verbetering geeft van littekens en aan littekens gerelateerde klachten zoals pijn. Daarom hebben we in hoofdstuk VI van dit proefschrift de huidige literatuur over de regeneratieve effecten van het ingespoten getransplanteerde vet en de ASC besproken. Deze grondige analyse van de literatuur toonde aan dat het gebruik van lipofilling en ASC de negatieve effecten van 'verse' evenals pre-existente fibrotische littekens doet verminderen. Definitieve conclusies konden echter nog niet worden gemaakt vanwege de grote verscheidenheid in de studieontwerpen in al deze geanalyseerde publicaties. Jammer genoeg ontbreken er dus nog steeds up-to-date gerandomiseerde gecontroleerde klinische onderzoeken over het gebruik van lipofilling, ASC, Stromal Vascular Fraction of ASC-geconditioneerd medium voor fibrotische littekenbehandeling. Daarom menen we dat het juist nu van groot belang is om dergelijke klinische onderzoeken te starten en op te zetten op een gerandomiseerde gecontroleerde manier zodat we eindelijk eens kunnen bepalen wat de effecten nu daadwerkelijk zijn en wat een optimale bron van stromale cellen zou kunnen zijn voor dit gebruik.

---

---

# ADDENDUM

- DANKWOORD (ACKNOWLEDGMENTS) -

- CURRICULUM VITAE -

***‘Luctor et Emergo’***

Dit proefschrift is opgedragen aan mijn vader, moeder en zus.

Dank voor jullie onvoorwaardelijke steun en liefde.

---

## Dankwoord (acknowledgements)

De formatie van dit proefschrift is een 'team effort' geweest: zonder de energie, de begeleiding en de inzet van een groot aantal mensen was dit nooit mogelijk geweest. Een aantal personen wil ik persoonlijk onder de aandacht brengen.

### **Weledelzegeleerde heer, Dr. H.P.J.D. Stevens**

Beste Jeroen, wat met een 'Irisch' aan de bar tijdens het Corpsdiner begon heeft geresulteerd in dit proefschrift. Mede door jouw tomeloze enthousiasme, drive en inventiviteit, is dit proefschrift verwekt èn geboren. Het was een ongelofelijke reis, jouw enthousiasme en mijn wetenschappelijk blik zijn een gouden combinatie. Ik kijk met trots terug op alles wat we samen hebben gepresteerd, en ben je hier dankbaar.

Een beschrijving van jouw als persoon is het best verwoord met een quote uit Fear and Loathing in Las Vegas, door Hunter S. Thompson:

*"There he goes. One of God's own prototypes. A high-powered mutant of some kind never even considered for mass production. Too weird to live, and too rare to die."*

Merci amice, bij deze de laatste punt achter het laatste woord van de laatste zin.

### **Hooggeleerde heer, Prof. dr. B. van der Lei**

Beste Berend, Vanaf het eerste moment hadden wij een click. Door jouw leiding, overzicht en nuchterheid is een prachtig proefschrift tot stand gekomen. Onze 'sparring sessions' waren altijd leerzaam, effectief en gezellig.

De trip naar Berlijn was legendarisch, en is een herinnering die ik koester: het gezette record Polen-Groningen in een V8 Volvo XC90 gaat nooit worden verbroken.

Ik prijs jouw begeleiding, kennis en ben dankbaar voor de vriendschap die wij hebben opgebouwd.

Berend, merci!

### **Hooggeleerde heer, Prof. dr. M.C. Harmsen**

Beste Marco, zelden kom je iemand tegen met de kennis en passie die jij bezit, met daarbij het vermogen om dit over te brengen. Zonder enige basale kennis en of lab-technische kunde begon ik aan ons avontuur. De tijd in CAVAREM heeft mij gevormd als wetenschapper. De celbiologische 'point of view' in combinatie met een klinische blik, heeft geresulteerd in prachtige studies. Het is bewonderingswaardig te noemen hoeveel geduld, tijd en geld u in ons project heeft gestoken. Alles versterkt door de fantastische inhoudelijke discussies op uw kamer, met een borrel op zijn tijd. Zonder uw leiding, en de steun van de hele CAVAREM ploeg, was dit nooit en te nimmer gelukt, waarvoor dank. In twee jaar tijd heb ik ongelofelijk veel kunnen leren, en lol gehad met mijn 'lab buddies'.

Ik kijk uit naar hetgeen wat komen gaat: de toekomst is reconstructie op een cellulair niveau. Dit proefschrift is slechts het begin, en ik verheug me op onze toekomstige projecten.

**Prof. dr. P.M.N. Werker**, beste Paul. Mijn dank gaat uit naar het vertrouwen en de kansen die u mijn heeft gegeven.

De leden van de beoordeling commissie: **Prof. dr. D. Ulrich, Prof. dr. R. van der Hulst en Prof. dr. R.A. Bank**.

**Maroesjka Spiekman** en **Joris van Dongen** voor de fantastische samenwerking binnen 'Fat Cool', en de vriendschap.

De stafleden en medewerkers van de afdeling Plastische en Reconstructieve chirurgie UMCG, voor de prettige samenwerking en ondersteuning. Met een bijzondere vermelding voor **Elisabeth Sijbesma**. Dank allemaal.

De stafleden en medewerkers van de afdeling Pathologie en Medische Biologie UMCG.

De collega's onderzoekers van de Plastische: **Evert-jan ten Dam, Rosanne Lanting, Dieuke Broekstra, Sophie Post** en **Shariselle Pool**. Ga jullie missen ;-)

Al de collega's van CAVAREM waarmee ik samen heb gewerkt met bijzondere vermelding voor het 'buiten koffie groepje' **Guido Krenning, Jan-Reinier Moonen, Mojtaba Parvizi** en **Vincenzo Terlizzi**.

De laboranten op het lab die mij altijd hebben geholpen als ik weer aan het klungelen was met een experiment: **Josee Plantinga, Marja Brinker** en **Linda Brouwer**.

De directie van Bergman Clinics, specifiek de CEO **Bart Malenstein** voor de financiële ondersteuning en actieve participatie bij dit project. De medewerkers van de vestiging Uiterlijk en Huid Bergman Clinics Den Haag voor het faciliteren van de RCT. Zonder jullie inzet en flexibiliteit was dit nooit gelukt!

Mijn oude opleiders chirurgie uit het Martini ziekenhuis, **Wendy Kelder** en **Paul Keller**, voor hun continue support tijdens het overstappen naar de radiologie.

De ondersteuning van Zimmer-Biomet voor de RCT. Helaas is **Arjan van den Hill** niet meer onder ons, ik wil even stilstaan bij dit feit: zonder hem was dit nooit van de grond gekomen. Daarnaast dank aan **Cahit Akbas** voor de praktische ondersteuning tijdens het draaien van de RCT.

De collega ass. chirurgie tijdens de vooropleiding in het Martini Ziekenhuis.

De opleiders radiologie ASZ Dordrecht, **Dr. Tadek Hendrisz** en **Dr. Nienke Katier** voor het bieden van de nieuwe kans.

Al mijn vrienden en kennissen, **you know who you are :-)**

Merci! X Joep

## Curriculum Vitae



Joep C.N. Willemsen was born on the 11th of October 1984 in Zevenaar. After attending the Liemers lyceum in Zevenaar he started his medical training in 2003 at the Erasmus University Rotterdam.

During his active student years, both at the fraternity but also scientifically, he teamed up with Dr. Jeroen Stevens to pursue a doctorate and residency position in Plastic Surgery. This eventually led to collaboration with Prof. Berend van der Lei from the department of Plastic and Reconstructive surgery UMCG, making Groningen his new home.

The collaboration with the CAVAREM group of Prof. Marco Harmsen, resulted in a 2 year fundamental project that is part of this thesis. With his efforts, he was offered a residency position, starting with 2 years of general surgery training at the Martini Hospital. After two years he decided to switch to a specialization that suited him better, Radiology.

During the latter period, he completed his thesis, with publications in relevant journals, and receiving international acclaim for his work.

Nowadays he works as a Radiology resident at the Albert Schweitzer Hospital Dordrecht, returning to his much beloved hometown Rotterdam.

## Other publications by this author

**What is the current optimal fat grafting processing technique? A systematic review.**

*Tuin AJ, Domerchie PN, Schepers RH, Willemsen JCN, Dijkstra PU, Spijkervet FK, Vissink A, Jansma J.*

*J Craniomaxillofac Surg. 2016 Jan;44(1):45-55.*

**Triple Layer Midface Lifting – Long Term Follow Up of an Effective Approach to Aesthetic Surgery of the Lower Eyelid and the Midface.**

*dr.H.P.J.D Stevens en J.C.N. Willemsen*

*Aesthetic Plast Surg. 2014 Aug;38(4):632-40.*

**Lipofilling: het levende goud?**

*dr.H.P.J.D Stevens en J.C.N. Willemsen*

*Nederlands Tijdschrift Voor Plastische Chirurgie. (03)-2013, 96-103*

**Results and long-term patient satisfaction after gluteal augmentation with platelet-rich plasma-enriched autologous fat.**

*Willemsen JCN, Lindenblatt N, Stevens HP.*

*Eur J Plast Surg. 2013;36:777-782. Epub 2013 Sep 1.*

**Unilateral versus bilateral correction of unicoronal synostosis: an analysis of long-term results.**

*Cornelissen MJ, van der Vlugt JJ, Willemsen JCN, van Adrichem LN, Mathijssen IM, van der Meulen JJ.*

*Journal of Plastic Reconstructive and Aesthetic Surgery 2013 May;66(5):704-11*

**On the origin of bitemporal hollowing.**

*van der Meulen JJ, Willemsen JCN, van der Vlugt J, Nazir PR, Hilling D, Mathijssen IM, Ongkosuwito E, van Adrichem LN, Vaandrager MJ, Hovius SE*

*Journal of Craniofacial Surgery 2009 May;20(3):752-6.*







**TUSSENSCHIET:**

*DIT VEL WORDT TIJDENS DE  
AFWERKING VERWIJDERD*

**SEPARATION:**

*THIS SHEET WILL BE REMOVED  
DURING THE BINDING PROCESS*





**TUSSENSCHIET:**

*DIT VEL WORDT TIJDENS DE  
AFWERKING VERWIJDERD*

**SEPARATION:**

*THIS SHEET WILL BE REMOVED  
DURING THE BINDING PROCESS*





